Well-defined osteolytic tumors: A review of clinical aspects, imaging findings, differential diagnosis and therapeutic options

Poster No.: C-1260

Congress: ECR 2014

Type: Educational Exhibit

Authors: Y. Costa[1], L. Andrade[2], M. Magalhaes[2], M. Diniz[1], J. F. Pisco[1], L. Curvo Semedo[2], C. B. Marques[2], F. Caseiro Alves[2]; [1]Faro/PT, [2]Coimbra/PT

Keywords: Infection, Cancer, Diagnostic procedure, MR, CT, Conventional radiography, Bones

DOI: 10.1594/ecr2014/C-1260

Learning objectives

1 To discuss a systematic approach and differential diagnosis for well-defined osteolytic tumors.

2 To review the main clinical features of these lesions.

3 To illustrate and review the key multimodality imaging findings of well-defined osteolytic tumors and tumor-like lesions and their therapeutic options.

Background

The well-defined osteolytic bone lesions are referred as "bubbly lesions" and are relatively common findings skeletal radiographs

It's crucial to perform a systematic approach of these lesions according primarily to their morphological radiographic aspects, age of the patient and location of the lesion.

For the purpose of this educational exhibit, only the most frequent histological subtypes will be discussed.

Findings and procedure details

A multimodality imaging approach is often necessary to better characterize the lesion and extent of the disease, but the standard radiography is essential and sometimes can be enough to suggest a short differential diagnosis if not a single diagnosis.

Table 1: Differential Criteria for Benign Osteolytic Bone Lesions Mnemonic: FEGNOMASHIC			
Fibrous dysplasia: No pain or periosteal reaction; if in tibia, mention adamantinoma			
Enchondroma: Presents with calcification, except in phalanges; no pain or periostitis			
Eosinophilic granuloma: Must be younger than 30 years			
Giant Cell Tumor: Epiphysis must be closed; should be epiphyseal/metaphyseal and abut the articular surface; eccentric; well-defined but non-sclerotic border			
Non-ossifying fibroma: Younger than 30 years; no pain or periostitis			
Osteoblastoma: Mention when aneurysmal bone cyst is considered, even if the patient is older than 30 years			
Metastatic disease and Myeloma: Older than 40 years.			
Aneurysmal bone cyst: Younger than 30 years; expansible			
Solitary bone cyst: Central location; younger than 30 years; no pain or periostitis			
Hyperparathyroidism (Brown tumor); Evidence of hyperparathyroidism			
Infection: If adjacent to a joint, must involve the joint (weak)			
Chondroblastoma: Younger than 30 years; epiphyseal			
Chondromyxoid fibroma: Mention when considering non-ossifying fibroma			
Younger than 30 years	**No Periostitis or Pain**	**Epiphyseal**	**Multiple lesions**
Eosinophilic granuloma	Fibrous dysplasia	Chondroblastoma	Fibrous dysplasia
Aneurysmal bone cyst	Enchondroma	Infection	Eosinophilic granuloma
Non-ossifying fibroma	Non-ossifying fibroma	Giant cell tumor	Enchondroma
Chondroblastoma	Solitary bone cyst	Geode	Metastasis and myeloma
		(Eosinophilic and Aneurysmal bone cyst are optional)	Hyperparathyroidism
			Infection

Table 1: Table 1: Differential Criteria for Benign Osteolytic Bone Lesions Mnemonic: FEGNOMASHIC (Adapted from Helms C. Fundamentals of Skeletal Radiology. 3th edition, Elservier 2004.)
References: Medical Imaging Department and Faculty of Medicine, Serviço de Radiologia do Centro Hospitalar do Algarve - Faro/PT

Fibrous dysplasia

Fibrous dysplasia is a benign tumor-like proliferation of fibro-osseous tissue. This disorder affects mainly children and young adults without gender predilection. Approximately 75% of affected patients are under the age of 30 years old.

The aetiology is unclear. It is believed to be caused by a mutation in a cell surface protein that inhibits the differentiation of immature bone to mature bone.

It can look like anything, frequently presenting with a long lesion in a long bone (monostotic form) during the patient growth and with slow enlargement after it.

Monostotic form occurs in 75 to 80% of cases, commonly asymptomatic until second-third decades. It generally becomes inactive after puberty and does not progress to polyostotic form.

An earlier diagnosis (typically in childhood) is made when multiple bones are involved (Polyostotic form).

Fibrous dysplasia can affect any bone, but it is commonly recognised in the proximal femur, tibia, humerus, ribs, and craniofacial bones, usually in the diaphysis or metadiaphysis.

Frequently asymptomatic, especially in monostotic form, being coincidentally diagnosed in plain films. This disorder can be present with pain and swelling (may increase during pregnancy) or with pathologic fracture of the affected region. Skeletal deformities may be present as a result of repeated pathological fractures. It can cause compression and displacement of adjacent structures (craniofacial fibrous dysplasia).

McCune-Albright syndrome is associated with the polyostotic form (2-3%). This disorder is also associated with isolated endocrinopathy without full McCune-Albright syndrome precocious puberty in girls (hyperthyroidism, hyperparathyroidism, acromegaly, diabetes mellitus, Cushing syndrome, and growth retardation). Another known association is with Mazabraud syndrome, where soft-tissue myxomas appear near the affected bones.

The lesion is composed by a fibrocellular matrix of immature collagen with immature, inadequately mineralized bone.

Plain film

Well defined lytic lesion with a ground glass or hazy appearance of the matrix.

R
90

Fig. 1: Fibrous dysplasia. Frontal radiography of the right knee shows a well-defined lesion with sclerotic margins and hazy matrix in femoral diaphysis.
References: Serviço de Imagem Médica, Centro Hospitalar e Universitário de Coimbra, Faculdade de Medicina de Coimbra Medical Imaging Department and Faculty of Medicine, University Hospital of Coimbra, Portugal
No periosteal reaction or soft tissue mass

Focal thinning of the overlying cortex - "scalloping from within"

Calcifications

CT

Helps to assess the disease extension and presence of fractures

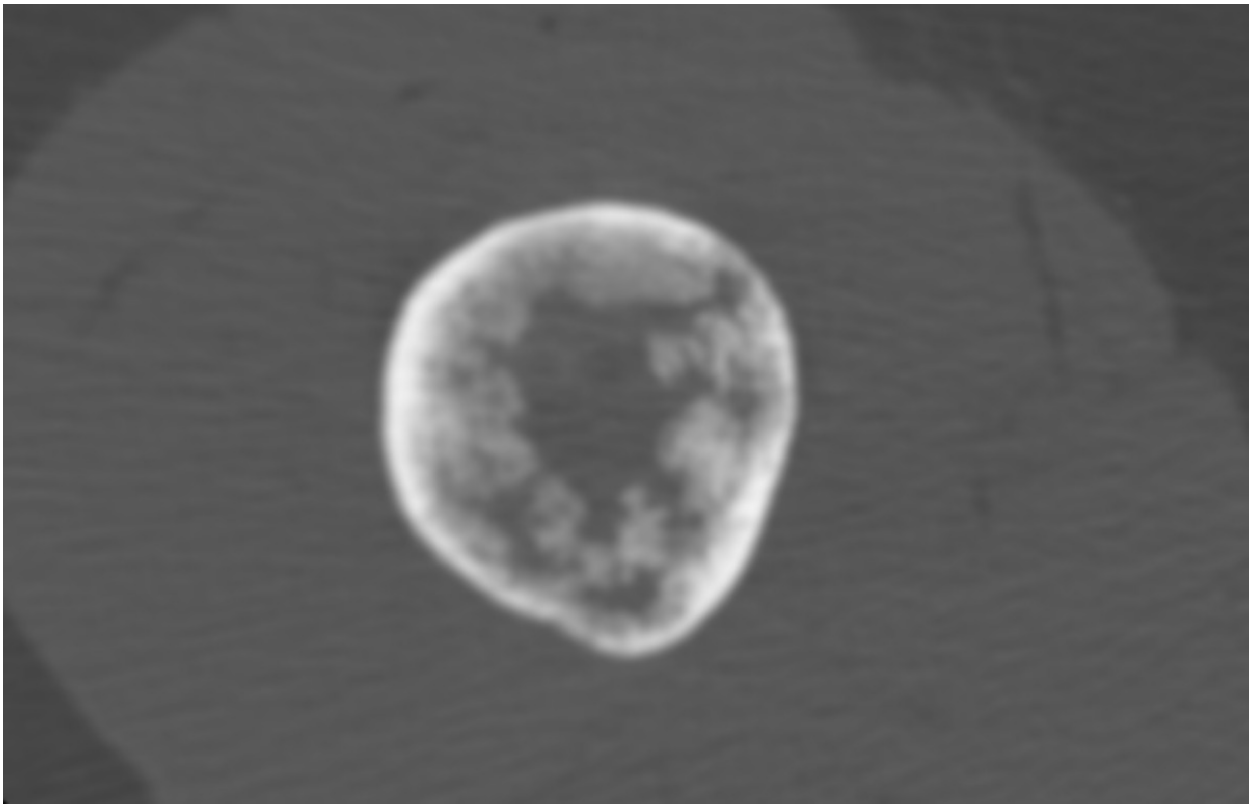

Fig. 2: Fibrous dysplasia. Axial computed tomography reformation image (B) of the same patient in figure 1.
References: Serviço de Imagem Médica, Centro Hospitalar e Universitário de Coimbra, Faculdade de Medicina de Coimbra Medical Imaging Department and Faculty of Medicine, University Hospital of Coimbra, Portugal
MRI

Helps to evaluate the lesion extension and may be useful differentiating fibrous dysplasia from other entities. Fibrous dysplasia presents with heterogeneous signal, usually

intermediate on T1-weighted images, with heterogeneous signal intensity on T2-weighted images and heterogeneous contrast enhancement.

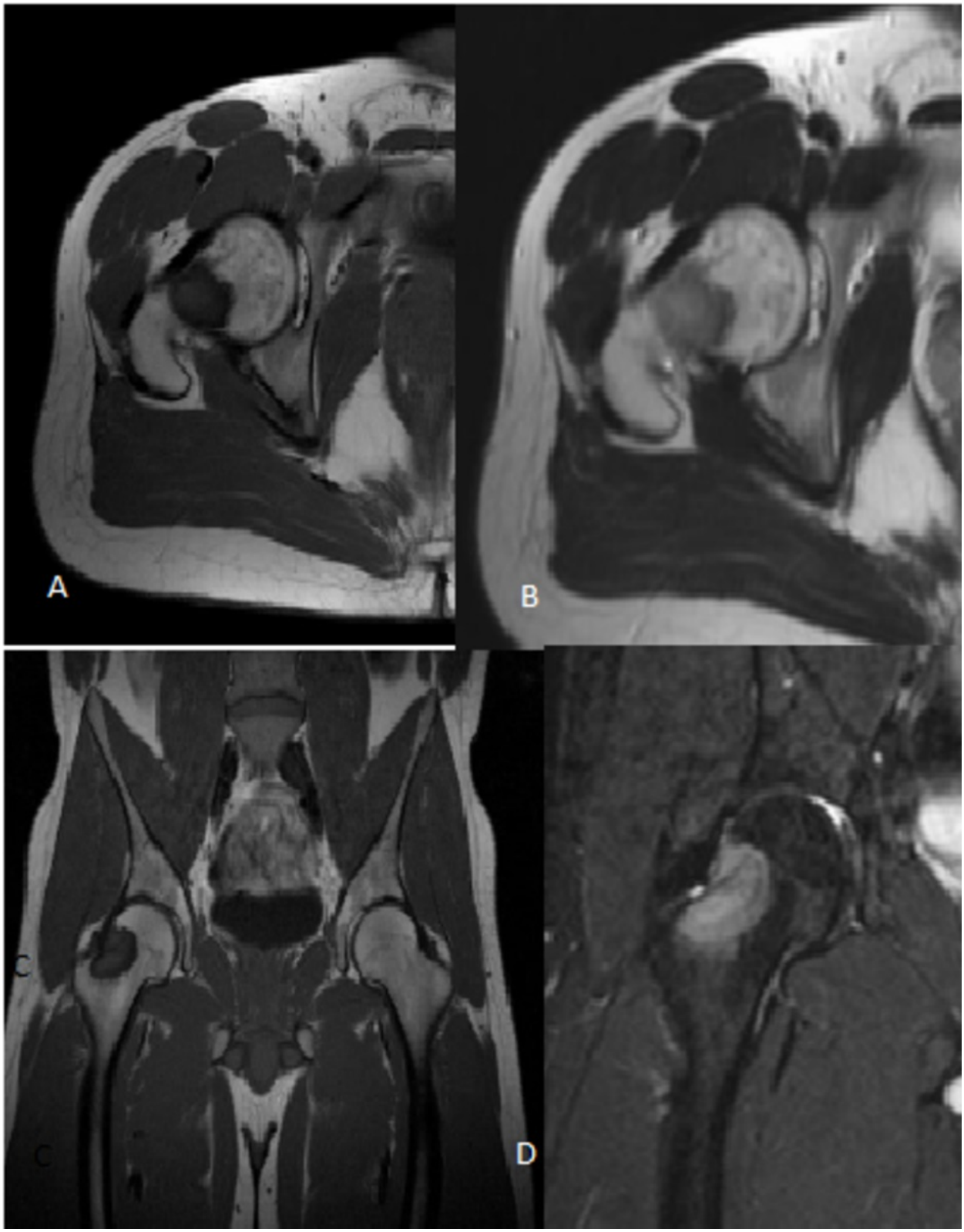

Fig. 3: Fibrous Dysplasia. Axial T1-weighted image, axial T2-weighted image. coronal T1 and T2-weighted without fat supression image reveal a small lesion in the right femoral neck. It presents with low signal intensity (A, C) and interme diate intensity of signal on T2-weighted image (B, D).
References: Serviço de Imagem Médica, Centro Hospitalar e Universitário de Coimbra, Faculdade de Medicina de Coimbra Medical Imaging Department and Faculty of Medicine, University Hospital of Coimbra, Portugal

Nuclear Medicine

Increased uptake on Tc99 bone (even after puberty)

As fibrous dysplasia can look like anything, the differential diagnosis is affected by the dominant feature, affected bone and patient age. The vast list of differential diagnosis include Paget`s disease, type I neurofibromatosis, adamantinoma, non-ossifying fibroma, simple bone cyst, giant cell tumour, enchondroma and aneurysmal bone cyst.

Biopsy confirms the diagnosis. The vast majority of patients do not require any type of treatment because the bone lesions frequently do not progress after puberty.

If mass effect is severe or if a high risk of pathological fracture exists, surgical treatment may be considered. After surgery, long-term biphosphates help reduce symptomatology and increase cortical thickness.

In less than 1% of cases of fibrous dysplasia, mostly in polyostotic form, occurs sacromatous de-differentiation (osteosarcoma, fibrosarcoma, malignant fibrous histiocytoma or rarely chondrosarcoma). In many of the reported cases the patient was exposed to radiation therapy.

Enchondroma

Enchondroma is a common benign medullary cartilage tumor of the bone (10% of all benign bone tumours). Enchondromas are composed of mature hyaline cartilage.

It is more common in patients on their twenties to forties, but can occur in any age without gender predilection.

It is frequently a coincidental finding because the majority of patients are asymptomatic. However it can be associated with pathologic fracture, pain and swelling. If an enchondroma is painful without an associated fracture, it should be considered malignant. Degeneration to chondrosarcoma occurs in 5% of the patients and is very rare in the extremities.

Enchondromas can occur in any bone formed from cartilage. It is especially frequent in the tubular bones of the hands or feet (50%). They are also common in long bones and

ribs. Axial skeleton is rarely involved. They may be central, eccentric, expansible or non-expansible.

Enchondromas have mostly metaphyseal or metadiaphyseal location in short tubular bones and central metaphyseal location, with or without diaphysial extension in long tubular bones.

In rare cases an enchondroma may be associated with cortical extension and exophytic growth pattern (enchondroma protuberans).

When multiple enchondromas are present, usually with limb or one side of the body preference, the diagnosis of Ollier disease should be made. Ollier disease is a very rare condition, more frequent in the early childhood. The radiological findings are similar to the solitary enchondroma, emphasizing that the multiplicity of the lesions can lead to significant deformity. It is associated with higher risk of malignant degeneration (10-25%).

If multiple enchondromas are associated with soft tissue hemangiomas, the diagnosis of maffucci's syndrome should be made. The association with malignant transformation is higher than in Ollier disease.

Plain film and CT

Small lytic lesions with non-aggressive features.

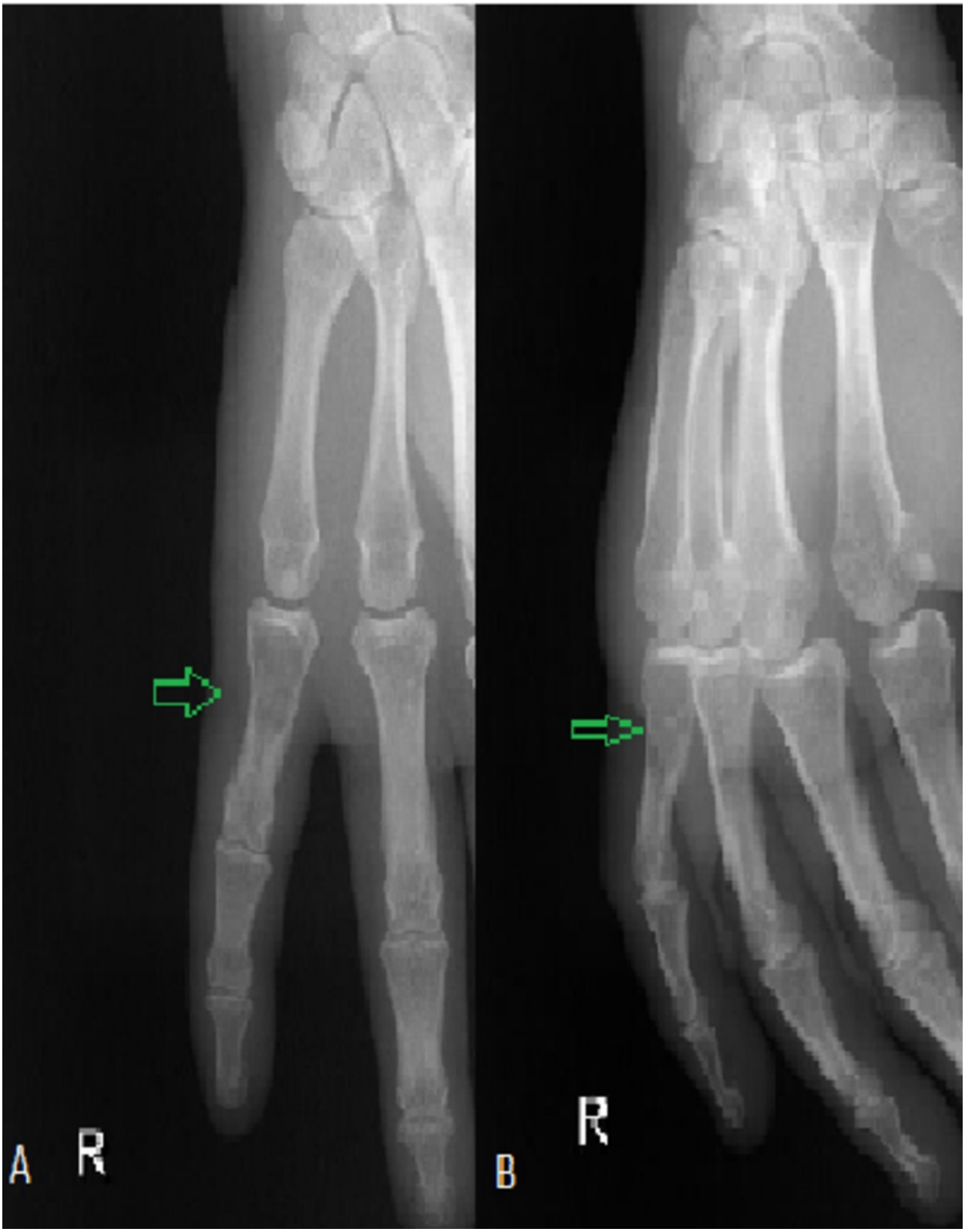

Fig. 4: Enchondroma. Anterior-posterior and lateral radiographs of the right hand reveals a well-defined lytic lesion located in the proximal phalange of the fifth finger (arrow).

References: Serviço de Imagem Médica, Centro Hospitalar e Universitário de Coimbra, Faculdade de Medicina de Coimbra Medical Imaging Department and Faculty of Medicine, University Hospital of Coimbra, Portugal

In the short tubular bones, enchondromas are usually associated with sclerotic rim a varying degree of chondrogenic calcifications ("arc and rings" calcifications). As for in the long tubular bones, the chondrogenic calcifications are usually denser. Absence of calcifications in certain location (phalanges of hand and feet)

No periosteal reaction or soft tissue mass associated.

CT helps to evaluate with a higher degree of confidence the cortical integrity and matrix calcifications.

Magnetic resonance

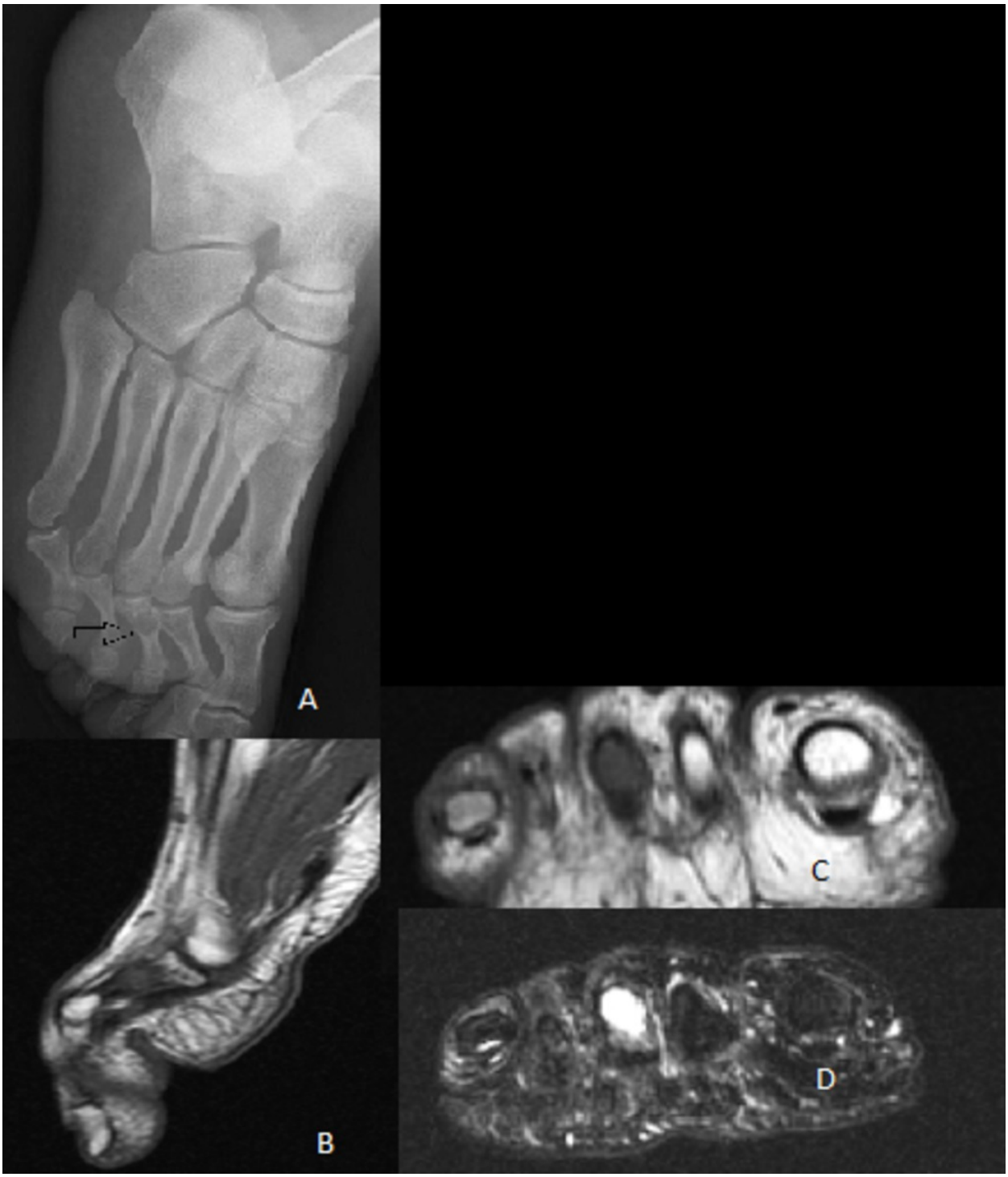

Fig. 5: Enchondroma. Oblique (a) radiography of the right foot show a well-defined lytic lesion, with a thin sclerotic border, in the proximal phalange of the third finger(arrow). T1 sagittal (B) and transverse (C) weighted images show a hypointense endomedular lesion in the proximal phalange of the third finger. The T2 transverse weighted image (D) reveals a hyperintense lesion in the same location. There is no soft tissue mass or invasion of the metacarpo-phalangeal joint associated.

References: Serviço de Imagem Médica, Centro Hospitalar e Universitário de Coimbra, Faculdade de Medicina de Coimbra Medical Imaging Department and Faculty of Medicine, University Hospital of Coimbra, Portugal

Enchondromas appear as well-circumscribed, slightly lobulated masses, replacing bone marrow, with high signal intensity on T2-weighted, which may have focal regions of signal drop out corresponding to the calcifications. They present with intermediate to low signal intensity on T1-weighted images, with variable enhancement mostly in the peripheral or translesional septae. No bone marrow or soft tissue oedema is associated.

The differential diagnosis is dependent of the location of the lesion and age of the patient.

If the lesion shows no matrix calcification and is located in the hand or feet, the differential diagnosis is made with giant cell tumor, epidermoid inclusion cyst, aneurismal bone cyst and fibrous dysplasia. In other locations, enchondroma can also be confused with bone infarct or low-grade chondrosarcoma.

Almost every lesion referred can be excluded with MRI, the exception being low grade chondrosarcoma.

Enchondroma versus low-grade chondrosarcoma

The differential diagnosis of this two entities is very difficult because there is considerable histologic and radiographic overlap.

Chondrosarcoma can occur as a malignant transformation within a cartilaginous tumour.

The findings that suggest the diagnosis are:

- Elderly patients

-Large size lesions (> 5 cm)

- Lesion-related pain.

- enlarging lesion in skeletally mature patients;

-deep endosteal scalloping (more than two thirds of cortical thickness)

- Cortical extension

- Periosteal reaction

-Fast enhancement on dynamic contrast enhanced MR series

- Soft tissue mass component;

- Activity on bone scan

The vast majority of enchondromas do not require any treatment (asymptomatic). When a fracture is detected, the bone may be allowed to heal. Biopsy should be performed in painful lesions without associated fracture or worrisome lesions, followed by intra lesional resection. Large defects can be filled with bone graft.

Eosinophilic granuloma

Eosinophilic granuloma is a non-neoplastic proliferation of histiocytes. The skeletal system is commonly involved in Langerhans cell histiocytosis.

This disorder is usually monostotic but infrequently may be polyostotic. It has female predilection (M: F 1:2) and commonly occurs in young children. This diagnosis can be excluded after the age of 30 years.

Eosinophilic granuloma frequently presents with local pain, swelling and tenderness of the affect region and general malaise with fever.

It is composed by Langerhans cells, eosinophils, lymphocytes and neutrophils.

The most common sites of involvement are the skull, mandible, spine and long bones.

This condition may progress to systemic forms of the disease.

Plain film

Skull - sharp, punched out borders solitary or multiple lytic lesions

With or without sclerotic rim

Double contour or beveled (greater involvement of the inner than the outer table)

Button sequestrum (residual bone)

Mandible - irregular lytic areas in the superficial alveolar bone

Spine - vertebra plana (thoracic spine)

Affect the vertebral body

Long bones - diaphysis respecting growth plates

Central lesion

Endosteal scalloping

Periosteal reaction

Cortical thinning

Intracortical tunnelling

Pelvic lesions - mostly poorly defined lytic lesions

CT

Help to assess the intramedullary and cortical extension

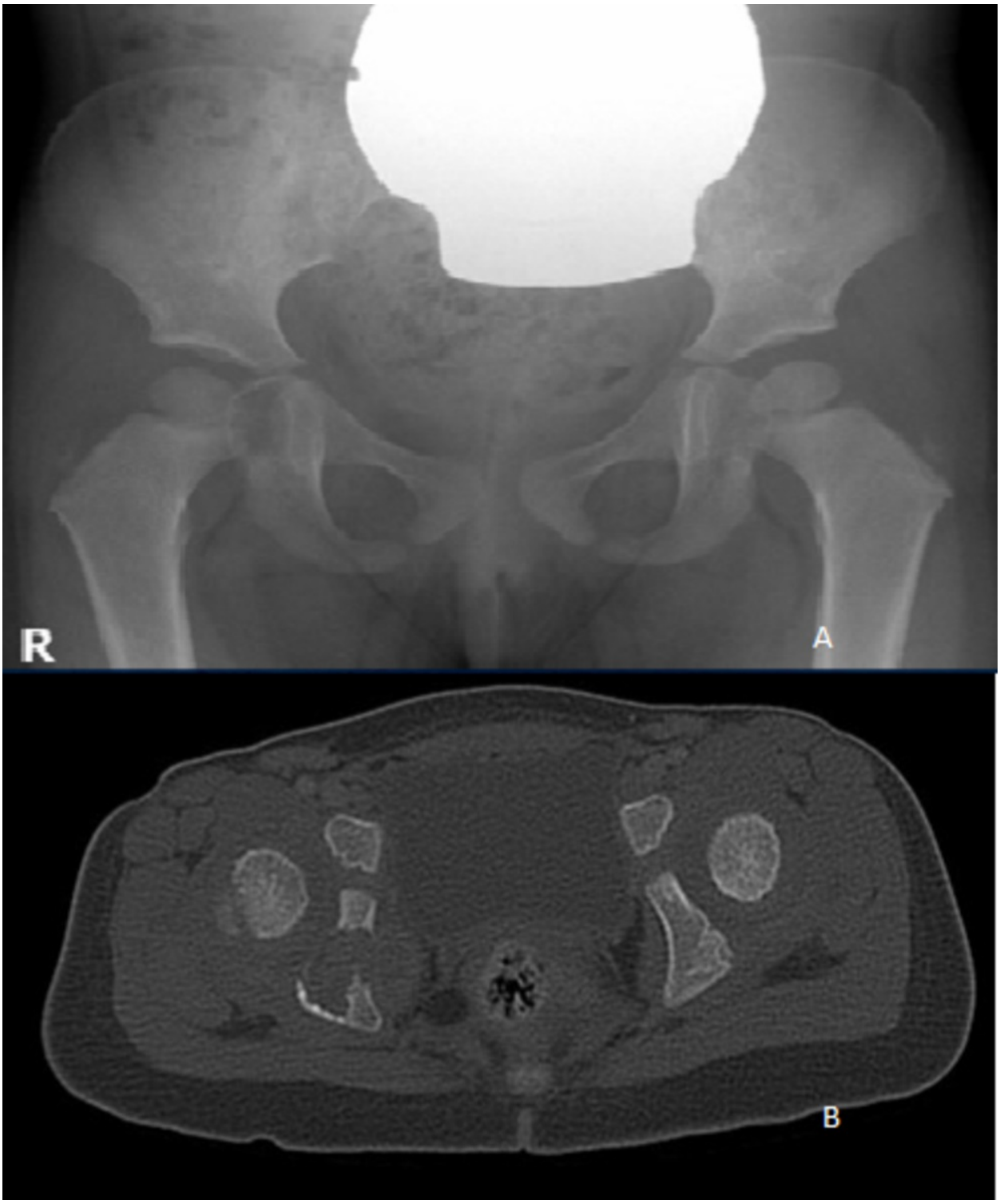

Fig. 6: Eosinophilic granuloma. Frontal radiography (A) shows a large well-defined lytic lesion in the right pelvic bone. Axial computed tomography (B) of the same patient reveals a large lytic lesion located in the right pelvic bone with cortical disruption.
References: Serviço de Imagem Médica, Centro Hospitalar e Universitário de Coimbra, Faculdade de Medicina de Coimbra Medical Imaging Department and Faculty of Medicine, University Hospital of Coimbra, Portugal

MRI

Help to assess the intramedullary and cortical extension

Eosinophilic granuloma presents typically with low signal intensity on T1-weighted images, isointense to hyperintense signal on T2 weighted images, and often shows contrast enhancement. Bone marrow oedema and pheripheral oedema.

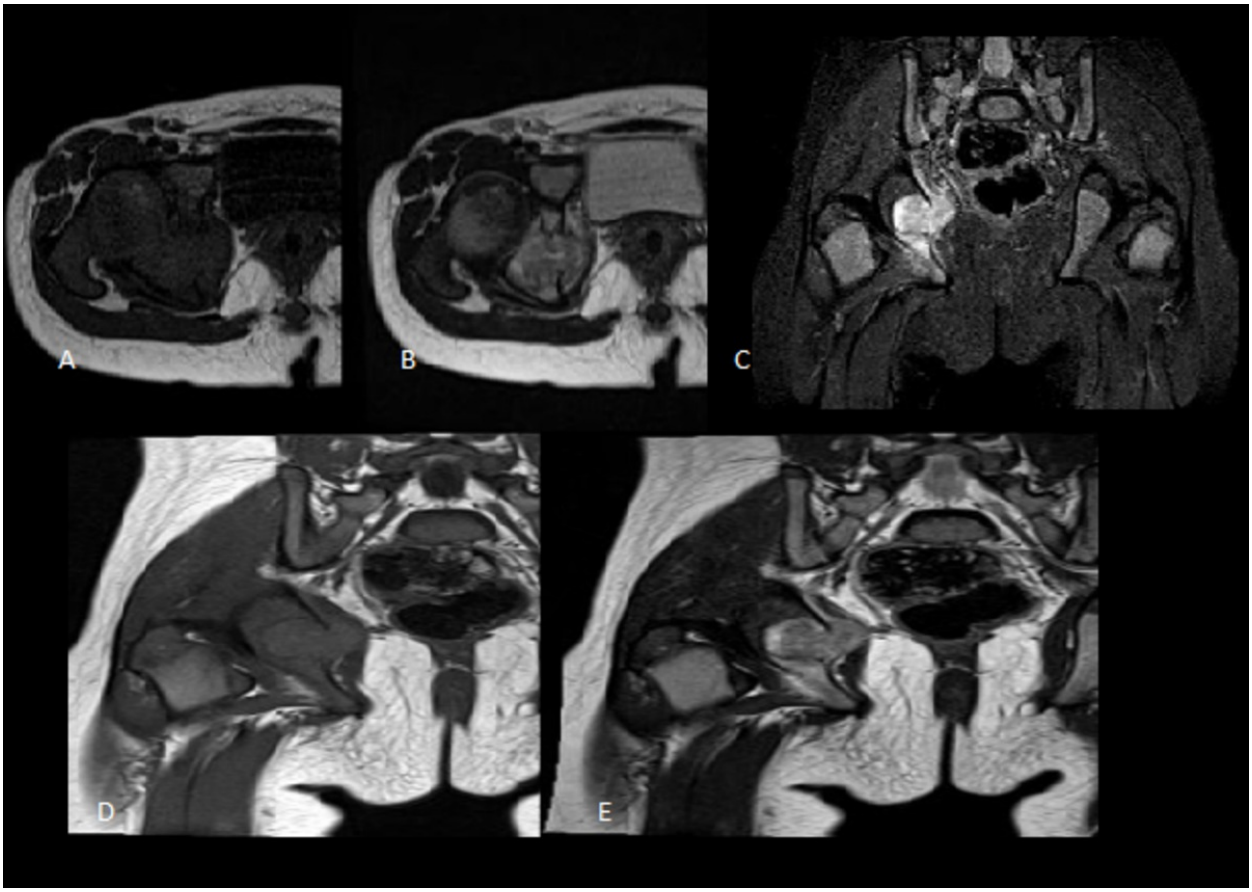

Fig. 7: Eosinophilic granuloma. This lesion presents with low intensity of signal on T1-weighted images (A,D) and slightly heterogeneous hyperintensity signal on T2-weighted images (B,E). There is bone marrow and surrounding muscle oedema (C).
References: Serviço de Imagem Médica, Centro Hospitalar e Universitário de Coimbra, Faculdade de Medicina de Coimbra Medical Imaging Department and Faculty of Medicine, University Hospital of Coimbra, Portugal

Bone Scan

Non-specific

Increased/decreased tracer uptake

The differential diagnosis includes Ewing's sarcoma, osteosarcoma, metastases and osteomyelitis. This condition should be considered in the diagnosis of any sclerotic or lytic lesion, well or ill-defined in patients under the age of 30.

When the disease is confined to the skeleton in solitary presentation it may spontaneously resolve with fibrosis. Nonetheless with persisting symptoms excision/curettage, steroid therapy, chemotherapy and radiofrequency ablation most be considered.

Giant Cell Tumor

Giant cell tumors account for 21% of benign bone tumors. The tumor is composed with mononuclear stromal cells and multinucleated giant cells. Although the majority of cases are benign there is an important risk of malignant degeneration into fibro or osteosarcoma (10-20%) mostly in patients with several local recurrences or in radiotherapy treated inoperable tumors. The malignant transformations signs are cortical disruption, spicular periosteal reaction, spur Codman, invasion of soft tissues and lung metastases.

This disorder has female predilection (spine), nonetheless malignant transformation is commoner in the male gender. The lesion invariably occurs after the closure of the growth plate so it is usually seen in early adulthood.

Clinical presentation is generally not specific, frequently with dull pain, swelling or pathologic fracture.

Usually present as a solitary lesion and can occur in any bone. The most common sites of topography are the epimetaphyseal bone near the knee (distal femur and proximal tibia) and bellow the elbow (distal radius).

The aetiology of this lesion is unclear. It is believed that it results from an over-expression in RANK/RANKL signalling pathway.

The radiologic appearance highly helps the diagnosis as it can be difficult to interpret the histological findings.

Classic appearance

In 95-98% of cases Giant cell tumours in long bones present these characteristics:

- Occur with closed growth plate
- Abuts articular surface
- Well defined non-sclerotic margin
- Eccentric location

Plain film and CT

Well-defined non-sclerotic margin

Eccentric location

Adjacent bone is thinned, expanded or deficient

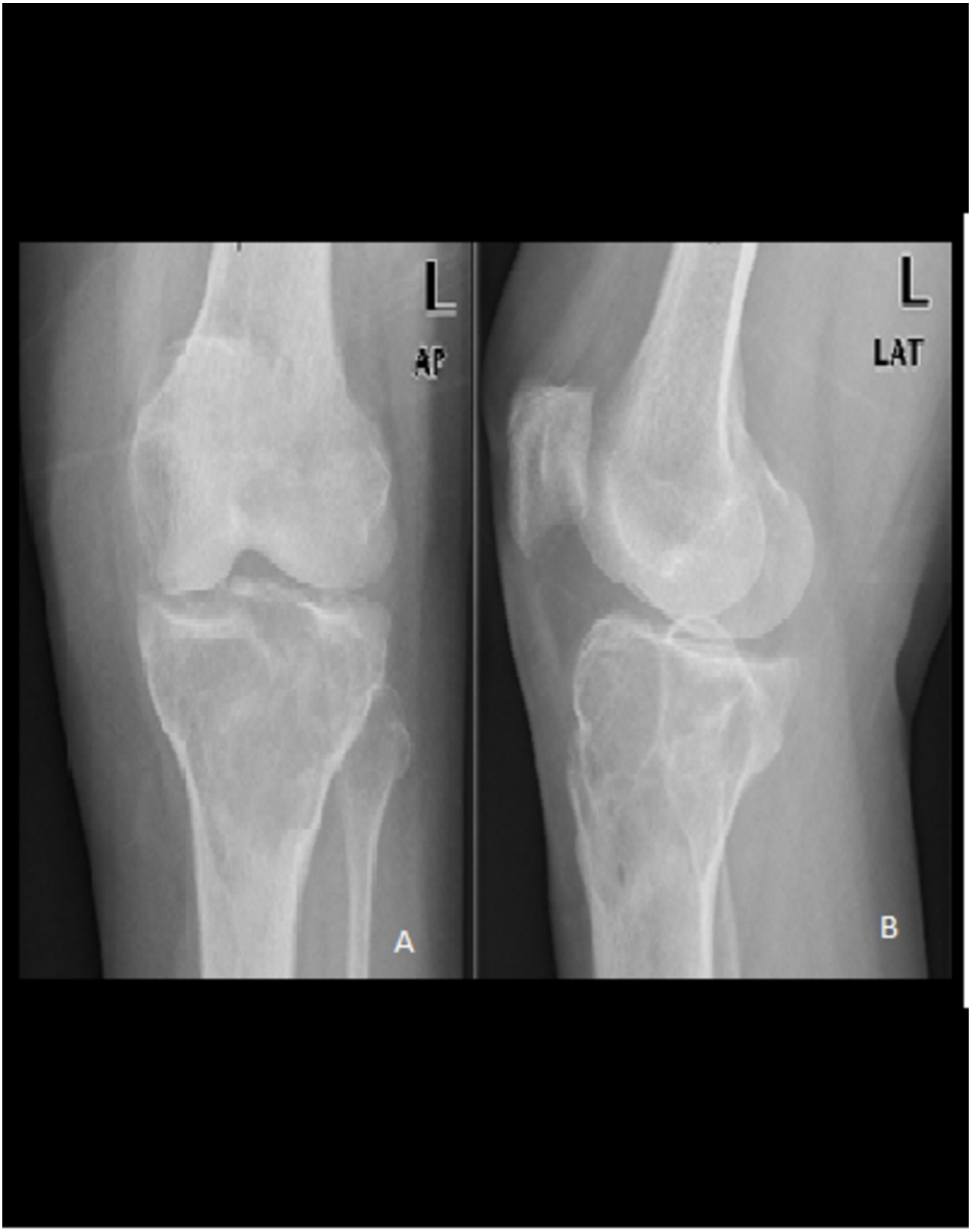

Fig. 8: Giant cell tumor. Frontal (A) and lateral radiographs of the left knee show a large geographic lytic lesion with a narrow zone of transition and no rim of sclerosis (arrowheads), with central location on the metaepiphyseal side of the closed growth plate in the distal left tibia.

References: Serviço de Imagem Médica, Centro Hospitalar e Universitário de Coimbra, Faculdade de Medicina de Coimbra Medical Imaging Department and Faculty of Medicine, University Hospital of Coimbra, Portugal

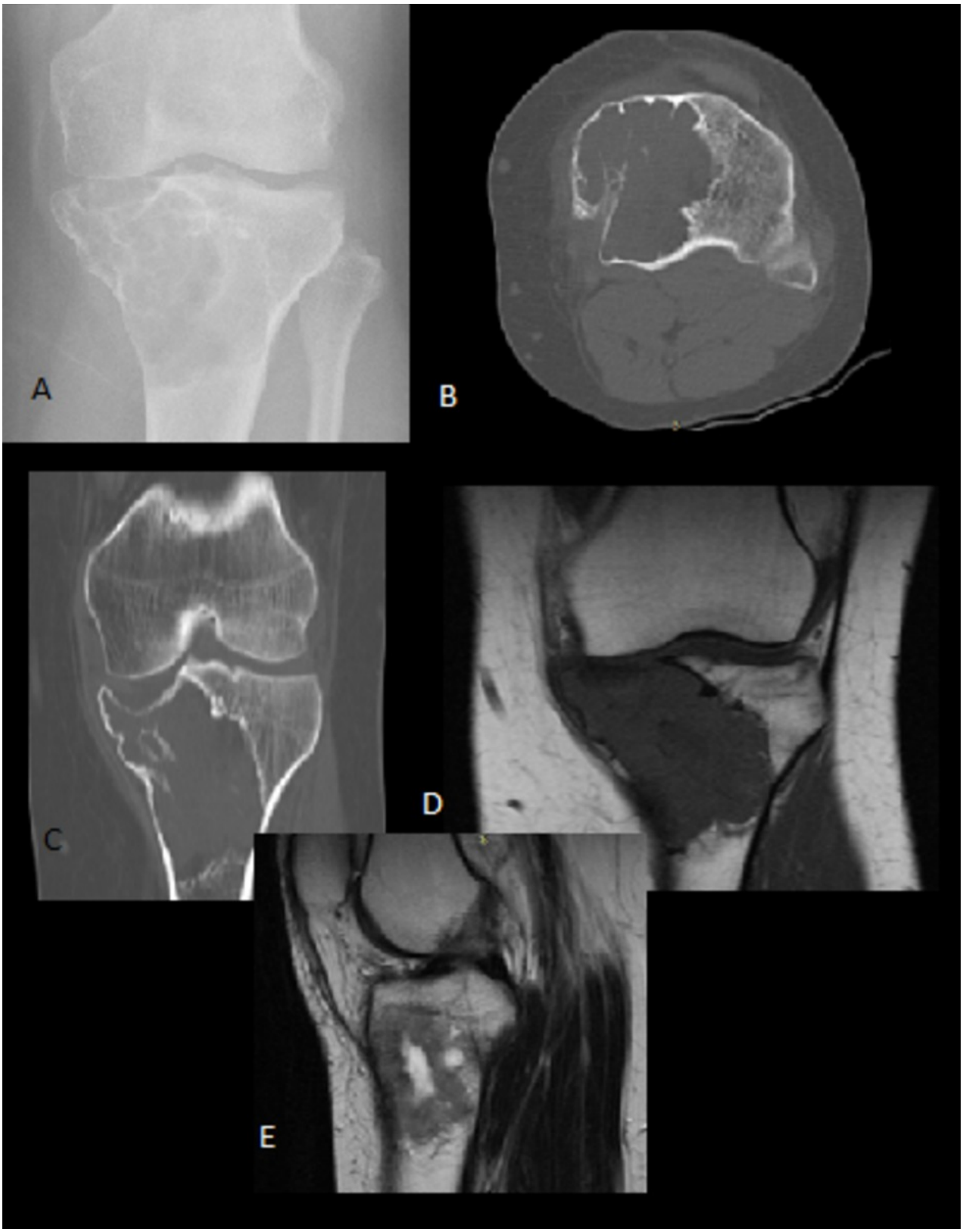

Fig. 9: Giant Cell Tumor. Anteroposterior radiograph (A) shows an eccentric lytic metaepiphyseal lesion in the distal tibia extending to subchondral bone. Axial computed tomography reformation (B) and coronal computed tomography reformation

(C)show a mild expansion and sclerosis about the giant cell tumor. Coronal T1-weighted image (D), sagittal T2-weighted image (E) reveal a lesion with predominantly low intensity of signal on T1 weighted image and intermediate signal intensity with several high-signal-intensity foci corresponding to small cystic areas.
References: Serviço de Imagem Médica, Centro Hospitalar e Universitário de Coimbra, Faculdade de Medicina de Coimbra Medical Imaging Department and Faculty of Medicine, University Hospital of Coimbra, Portugal

Often presents with periosteal reaction, soft tissue mass and pathological fracture may be present

No matrix calcification or mineralisation

Signs of aggressiveness: ill-defined lytic lesion with cortical disruption and soft tissue extension

MRI

Presents with low to intermediate signal intensity (solid component) on T1-weighted images

The solid components enhance - differentiates Giant cell tumor with Aneurysmal bone cyst from pure Aneurysmal bone cyst

Heterogeneous intermediate to high signal intensity on T2-weighted images.

Fluid-fluid levels - secondary aneurysmal bone cyst?

Bone scan

Increased peripheral uptake with photopenic central region - Doughnut sign (not specific)

Angiography

Hypervascular tumor (60%) or hypo or avascular tumor.

When the lesion presents al four radiological characteristics the differential diagnosis is very short. Otherwise the differential diagnosis is made with chondroblastoma, chondromyxoid fibroma, aneurysmal bone cyst, non-ossifying fibroma, brown tumour, enchondroma, haemophiliac pseudotumour, chondrosarcoma, metastases and multiple myeloma.

Classically this lesion is submitted to surgical treatment. A low-grade tumor should be treated with curettage and filling, as a radiological aggressive tumor or with early aggressive recurrence the treatment should be more aggressive, with resection and reconstruction.

Non-ossifying fibroma

Non-ossifying fibroma is the most common benign fibrous bone neoplasm, also known as fibroxanthoma. The smaller lesions are also known as fibrous cortical defect. It is commonly found in children and young adults, generally not seen after the age of 30 years old because they disappear with growth. It is more frequent in men (Sex ratio: 1.5 H / 1F). It is believed that many bone islands are healed non-ossifying fibromas.

The vast majority of patients are asymptomatic (coincidental finding), however larger lesions may be painful and predispose to pathological fracture.

The non-ossifying fibroma is often associated with Jaffe-Campanacci syndrome (multiple non ossifying fibromas associated with multiple cafe au lait spots in skin, mental retardation, hypogonadism or cryptorchidism, ocular disease and cardiovascular malformations). Neurofibromatosis is often associated with multiple non-ossifying fibromas.

Histology analysis reveals a highly cellular lesion, composed with spindle-shaped cells in a prominent storiform pattern and stromal tissue.

The radiographic appearance is frequently typical and in those cases additional imaging or biopsy should be avoided.

Plain film and CT

Well-defined asymmetrical, cortically based lytic lesions with a thin sclerotic rim

Often with multiloculated appearance

Generally located in the metaphysis, just distal to the physis.

Without periosteal reaction, Codman triangle, cortical breach or soft tissue mass associated

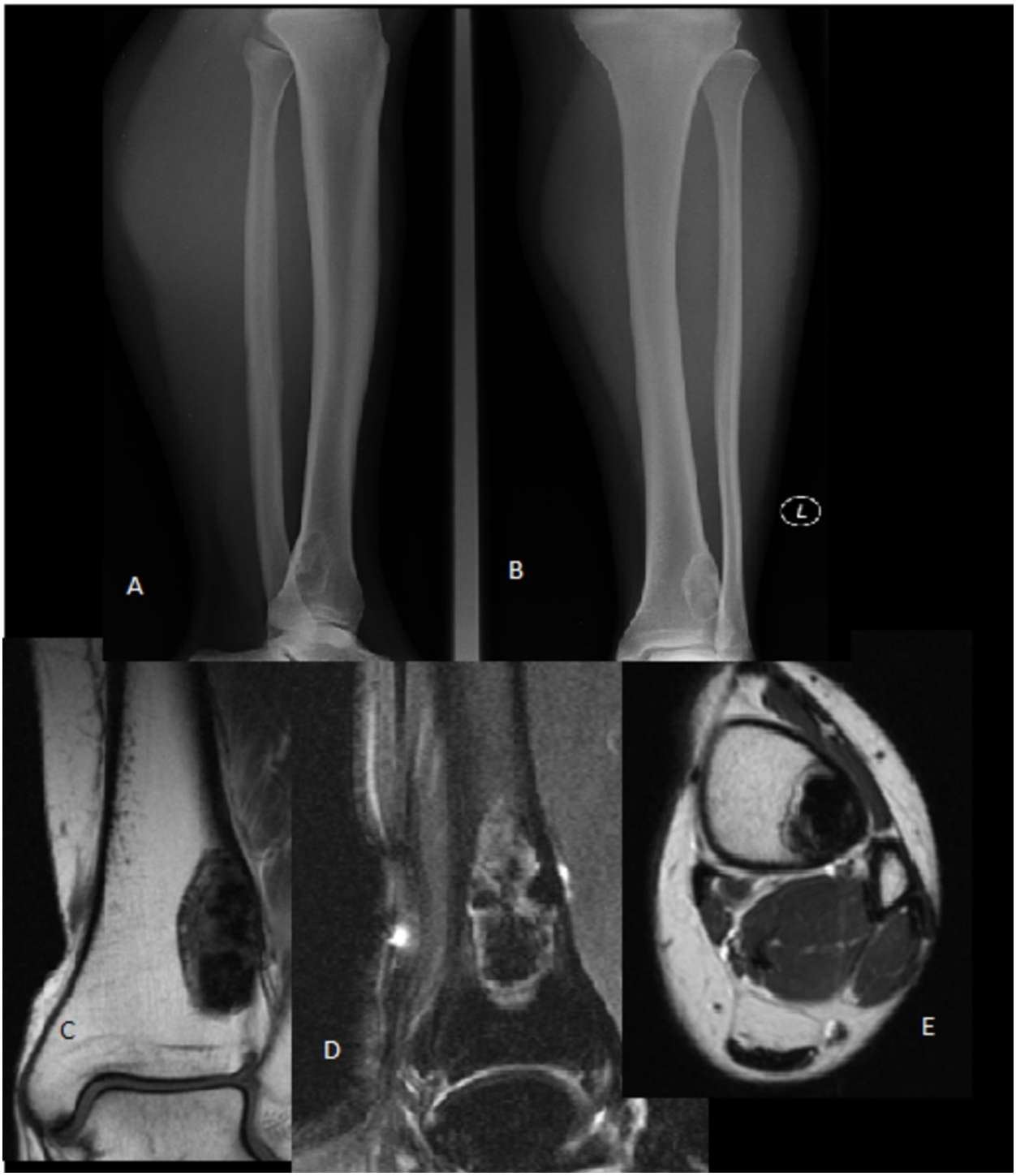

Fig. 10: Non-ossifying fibroma. Anterior-posterior (A) and lateral (B) radiographs of the left leg show a sharply demarcated asymmetrical, cortically based lytic lesion with a thin sclerotic rim, with slightly multiloculated appearance in the distal metadiaphyseal region of the left tibia. T1 coronal weighted image (C), T2 FS sagittal weighted image (D) and T2 axial weighted image (E)reveal a justacortical eccentric lesion, with well-defined borders and without cortical disruption. It is predominantly hypointense on

all sequences, with some outlying areas of hyperintensity of signal on T2-weighted images.
References: Serviço de Imagem Médica, Centro Hospitalar e Universitário de Coimbra, Faculdade de Medicina de Coimbra Medical Imaging Department and Faculty of Medicine, University Hospital of Coimbra, Portugal

MRI

Variable appearance regarding the phase when the lesion is characterized.

Immature lesion: has high to intermediate intensity of signal on T2-weighted images, with peripheral low intensity of signal (sclerotic rim)

Mature lesion: low signal intensity on T1 and T2-weighted images.

Variable type of contrast enhancement.

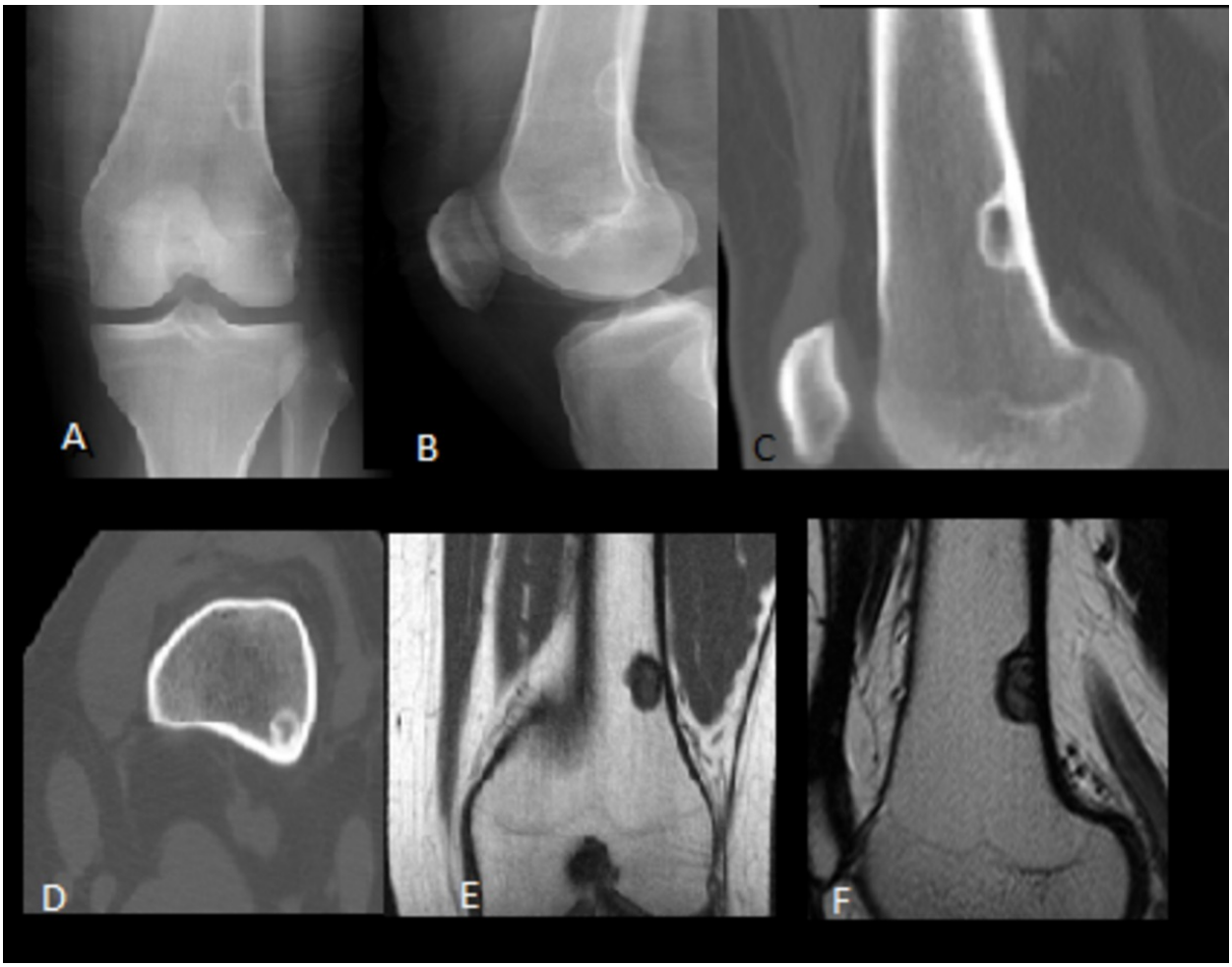

Fig. 11: Non-ossifying fibroma. Anterior-posterior and lateral radiographs of the left knee (A, B) show a small well-defined cortically based lytic lesions with a thin

sclerotic rim in the distal meta-diaphyseal of the left femur. Sagittal and axial computed tomography reformations (C, D) of the same patient continue to show a typical non-ossifying fibroma. T1 coronal weighted image and T2 sagittal weighted image (E, F) reveals the same lesion. hypointensity of signal on T1-weighted images and hypointensity of signal on T2-weighted images. Note the hypointense halo on both sequences. There is no associated soft tissue mass or cortical disruption.
References: Serviço de Imagem Médica, Centro Hospitalar e Universitário de Coimbra, Faculdade de Medicina de Coimbra Medical Imaging Department and Faculty of Medicine, University Hospital of Coimbra, Portugal

Bone scan

Immature lesions: generally negative.

Moderate bone uptake is present during healing.

When extensive uptake or hyperaemia is found, an alternative diagnosis or superimposed fracture should be considered.

Non-ossifying fibroma is a "Don't touch" lesion. However some lesions can simulate them as the aneurysmal bone cyst, chondromyxoid fibroma and fibrous dysplasia.

Generally there is no need for treatment for this lesion, nonetheless when symptomatic, or a large lesion, curettage and bone graft should be considered to avoid pathologic fracture.

Osteoblastoma

The osteoblastoma is a rare benign primary bone tumor, accounting for approximately 1-3% of primary bone tumours. This lesion has male predominance (H: F ratio 2.5:1) and occurs in young patients.

The clinical presentation depends on the location of the lesion. In spinal lesions painful scoliosis is a common sign. Lesions with other locations present with progressive dull pain, swelling and tenderness and restricted mobility of the affected region.

Osteoblastoma has a similar histological appearance as an osteoid osteoma, except for the size. It is much larger (> 2cm), which explains why it is also called "giant osteoid osteoma".

It is frequently located on the spine (posterior arch) and metaphysis or diaphysis of long bones (humerus, tibia and femur). They can have a wide range of radiographic patterns.

Plain film

Predominantly lytic lesions with a rim of reactive peripheral sclerosis

Generally expansible lesions with cortical destruction

Often associated with internal calcification or soft tissue mass

Peripheral sclerosis or periostitis in up to 50%

Secondary aneurysmal bone cyst in 20%

CT

Predominantly lytic lesions

Helps to assess the internal matrix mineralisation

MRI

Nonspecific

Generally hypo to isointensity of signal on T1 weighted images with areas of focal decreased signal intensity due to calcifications. On T2-weighted images appears with variable intensity of signal, mostly as an isointense to hypointense lesion with focal areas of decreased signal intensity of signal corresponding to calcifications. Due to the high vascularity of the tumour, normally there is an intense enhancement of the lesion and surrounding soft tissues.

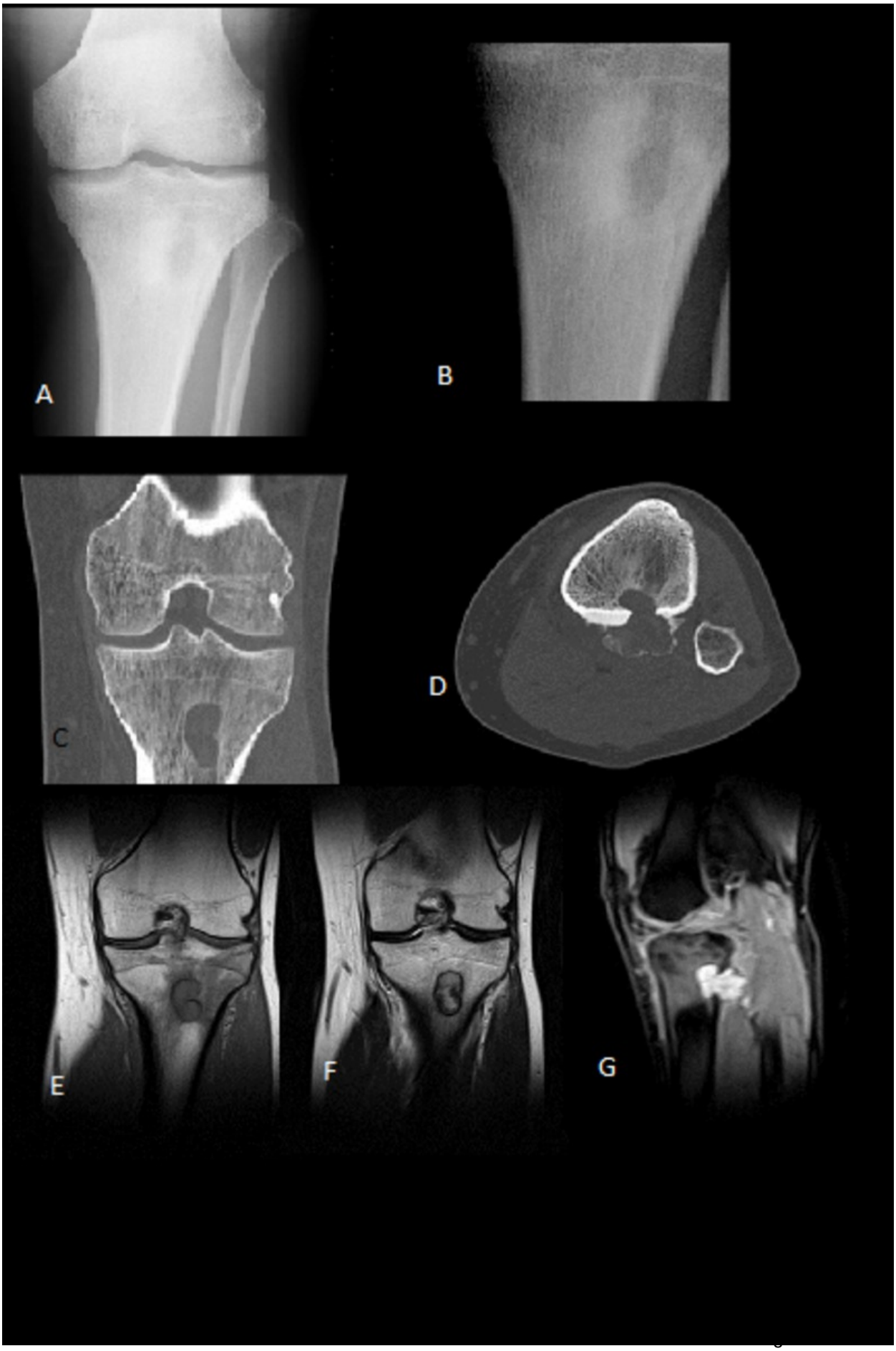
A
B
C
D
E
F
G

Fig. 12: Osteoblastoma. Frontal radiographs (A,B) show a lytic lesion with sclerotic pheripheral rim in the tibia. Coronal and axial computed tomography reformations (C, D) reveal a metaphyseal eccentric cortical lesion with calcified matrix. This lesion presents isointensity of signal on T1-weighted images (E) and slightly hyperintensity of signal on T2-weighted images (F), with surrounding bone marrow oedema. After gadolíneo administration (G) the lesion presents homogeneous enhancement.
References: Serviço de Imagem Médica, Centro Hospitalar e Universitário de Coimbra, Faculdade de Medicina de Coimbra Medical Imaging Department and Faculty of Medicine, University Hospital of Coimbra, Portugal

Nuclear medicine

Nonspecific

Intense uptake - normal in all lesions exhibiting increased bone turnover.

The differential diagnosis of osteoblastoma includes osteoid osteoma, osteosarcoma, giant cell tumour and aneurysmal bone cyst.

The treatment of choice is surgical resection by curettage, intra lesional excision or en-bloc excision. Depending on the topography of the lesion, sometimes is necessary to perform pre-operative embolization to reduce bleeding risk. The risk of reconstitution of collateral blood supply is high when surgical procedure is not done in short time interval after pre-operatory embolization. Unrespectable aggressive lesions (spine) should be treated with cryosurgery, radiation, chemotherapy, or a combination of these techniques.

Metastases and Multiple Myeloma

Lytic bone metastases

Metastatic disease should always be considered in the differential diagnosis of lytic lesion of patients over 40 years old, independently of benign or malignant appearance. They are the most frequent malignant bone tumours. If the patient is under 40 years old but has a previous history of malignant is necessary to include this disorder in the list of differential diagnosis.

The most common primary tumors that may originate lytic bone metastases are thyroid cancer, renal cell cancer, adrenal gland carcinoma, pheochromocytoma, uterine carcinoma, gastrointestinal carcinomas, Wilms tumour, Ewing sarcoma, melanoma, hepatocellular carcinoma and squamous cell carcinoma of the skin.

Usually patients are asymptomatic regarding the bone metastases, however it can manifest with local bone pain, palpable mass, deformity and pathological fracture(s).

The tumor spread to the bone is mostly haematogenous, although lymphatic spread is occasionally seen, in other cases direct extension to the bone is possible. Independently of the spread route the lytic bone lesions are likely to form from direct enzymatic destruction and osteoclast activation.

Plain film

Difficult to identify on plain films - 30-50% bone mineral loss is required before the density loss is visible

Generally are associated with limited or no periosteal reaction

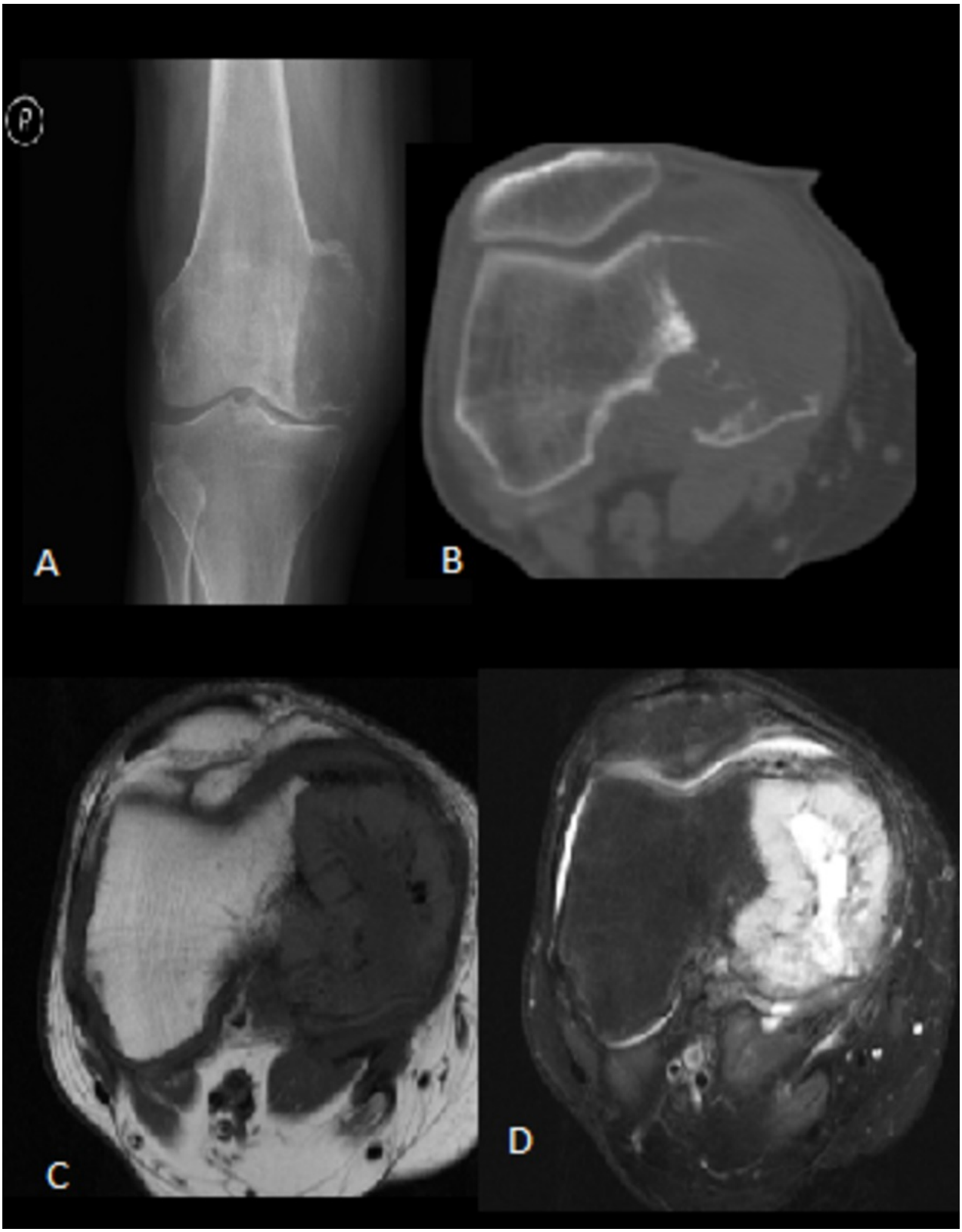

Fig. 13: Thyroid Carcinoma Bone Metastases. Frontal right Knee radiography (A) and axial computed tomography reformation (B) show a large lytic lesion, with eccentric location in the metaepiphyseal region of the medial femoral condyle. CT allows to

better appreciation of cortical disruption. Axial T1 (C) and axial T2- FS (D) weighted images show a heterogeneous lesion with central necrosis. There is small amount of joint effusion

References: Serviço de Imagem Médica, Centro Hospitalar e Universitário de Coimbra, Faculdade de Medicina de Coimbra Medical Imaging Department and Faculty of Medicine, University Hospital of Coimbra, Portugal

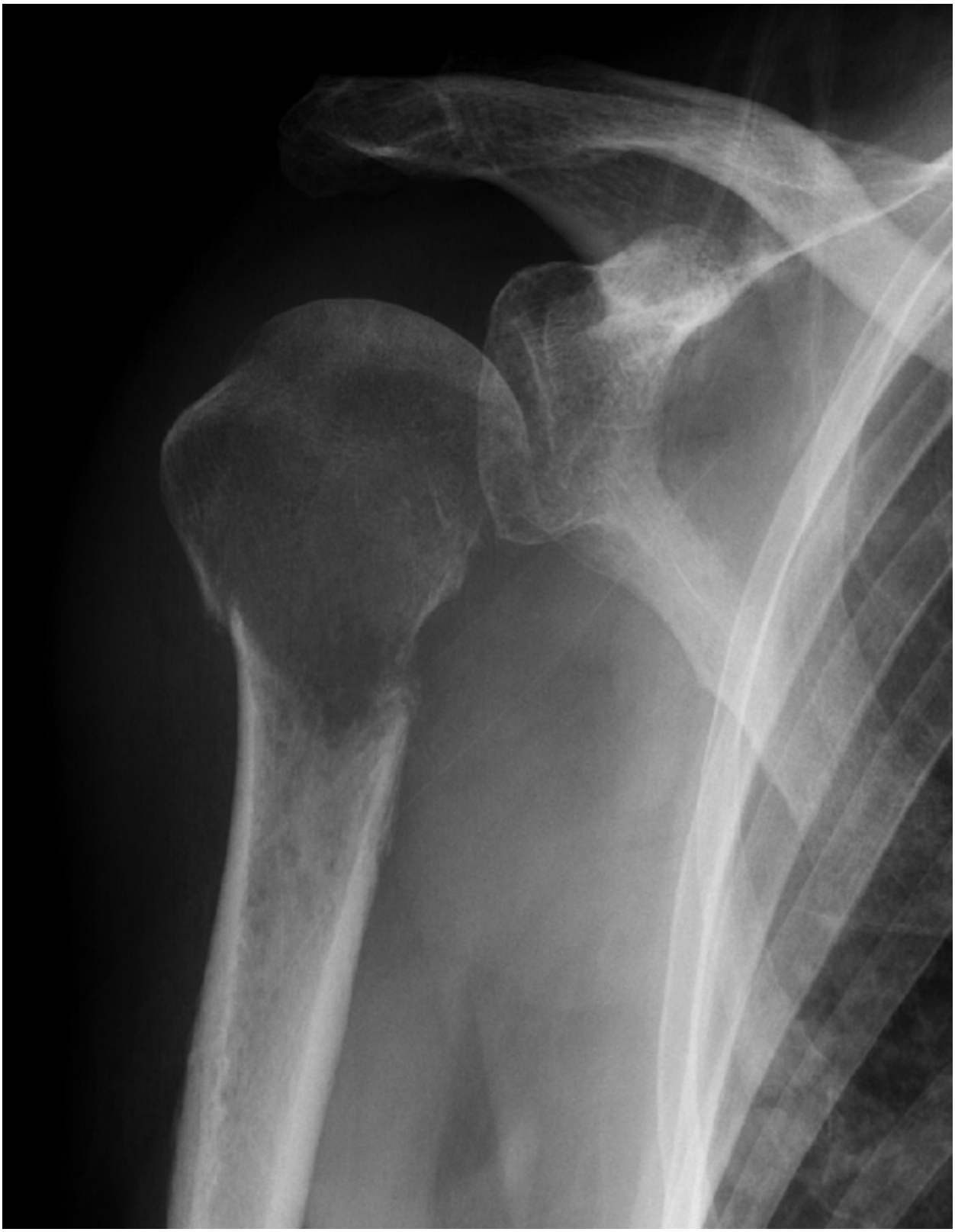

Fig. 14: Thyroid cancer bone metastases. Frontal radiography reveals a large lytic lesion with pathologic fracture located in the proximal humerus.

References: Serviço de Imagem Médica, Centro Hospitalar e Universitário de Coimbra, Faculdade de Medicina de Coimbra Medical Imaging Department and Faculty of Medicine, University Hospital of Coimbra, Portugal

CT

Helps to assess the extent of bone involvement and risk of pathological fracture

MRI

Highly sensitive to replacement of normal bone marrow

Nuclear medicine

Bone scans - most sensitive imaging modality

Increased uptake +++

Occasionally photopenic defect

Metastatic lytic bone disease has no distinct characteristic features. In an elderly patient with no history of malignancy and multiple lesions the main differential diagnose is made with multiple myeloma.

There are, unfortunately, no specific features of metastases, although often the diagnosis is straight forward in the setting of known advanced malignancy and multiple lesions.

When no history of malignancy is present, but lesions are multiple in an elderly patient, the main differential is multiple myeloma.

The treatment is commonly systemic with or without local treatment, besides that pain management is frequently needed. In cases where a structurally critical bone is highly affected may be necessary to provide extra surgical support (pining).

Multiple myeloma

Multiple myeloma is the most common primary malignant bone tumor in adults. Multiple myeloma should be included in the differential diagnosis list of a lytic bone lesion, regardless of the radiological appearance, in a patient over 40 years old. Approximately 70% of multiple myeloma cases are diagnosed between 50-70 years old patients, with male predominance (M: F 2:1).

Commonly affects the spine, skull, pelvis, ribs and the diaphysis of femur and humerus. Frequently presents as multiple lytic lesions.

It is divided in four forms regarding it`s radiological appearance:

- disseminated form with multiple defined "punched-out" lesions (axial skeleton)
- another disseminated form with diffuse skeletal osteopenia
- Solitary plasmacytoma (single large / expansible lesion - vertebral body or pelvis) à slightly younger population and typically progress to multiple myeloma.
- osteosclerosing myeloma

The clinical presentation is highly variable and may include bone pain, anaemia, renal failure / proteinuria and hypercalcaemia. The bony lesions may complicate with pathological fractures.

This condition results from monoclonal proliferation of malignant plasma cells that infiltrate haemopoietic locations and produce immunoglobulins.

Plain film (skeletal survey)**:**

The vast majority of lesions are purely lytic, well- defined / punched out with endosteal scalloping

Generalized osteopenia often associated with vertebral compression fractures

Sclerotic lesions

Plasmacytoma - sharply defined, "punched-out" lytic lesions, often with marked erosion, expansion and destruction of bone cortex

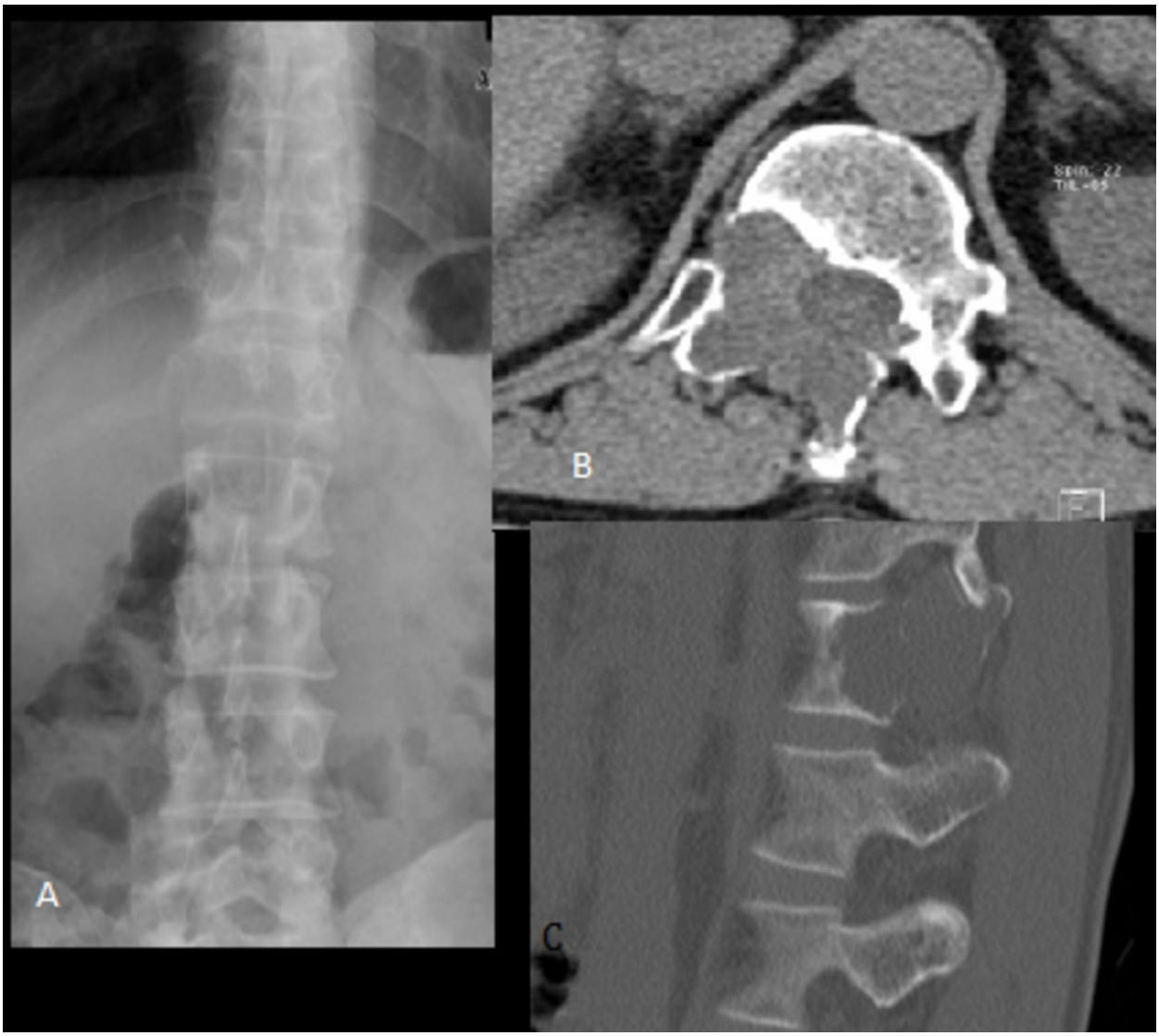

Fig. 15: Plasmacytoma. Frontal radiography (A) revealing a large well-defined lytic lesion in the first lumbar vertebra. Axial (B) and sagittal (C) computed tomography images allows better extension and cortical disruption assessment.
References: Serviço de Imagem Médica, Centro Hospitalar e Universitário de Coimbra, Faculdade de Medicina de Coimbra Medical Imaging Department and Faculty of Medicine, University Hospital of Coimbra, Portugal

CT

Helps to determine the extent of extra-osseous disease and assess the risk of fracture in severely affected bones.

MRI

More sensitive detection of multiple lesions

Better assessment of bone marrow infiltration and replacement.

Nuclear medicine

Bone scan - Does not show any uptake due to the lack of osteoblastic activity.

PET-CT

Identifies the disease distribution

The differential diagnosis is based mostly on the patient age and number of lesions, with multiple lesions the main differential diagnosis is metastases, with solitary lesion we should include giant cell tumor, lymphoma and tumours of chondroid origin.

In nowadays multiple myeloma remains an incurable disease. A combination of thalidomide, lenalidomide, bortezomib, cyclophosphamide, melphalan, prednisolone and doxyrubicin are used to treat this disorder. When clinically necessary, autologous stem cell transplant is performed in association with chemotherapy.

Aneurysmal Bone Cyst

An aneurysmal bone cyst (ABC) is a benign expansible tumor-like bone lesion. This term is purely descriptive, without any concept of pathogenesis or aetiology mechanisms. Presents as a blood-filled cavity, containing fibrous components, macrophages, giant cells and island of bone. In 80% of cases occurs in patients under 20 years old and are slightly more frequent in females than males.

The clinical presentation includes pain, with insidious onset or abrupt due to pathological fracture. There may exist a palpable lump or reduced mobility.

It is divided in primary aneurysmal bone cyst and secondary aneurysmal bone cyst. One third of the cases are secondary to an underlying lesion (can occur in any lesion - ++++ chondroblastoma, fibrous dysplasia, giant cell tumour and osteosarcoma).

This lesion can occur almost anywhere in the skeleton. The common topography sites are the femur, tibia, humerus, spine (posterior elements), and pelvis, and less frequently tumours arising in the small bones of the hands and feet. Frequently have an eccentric location in the metaphysis or diaphysis.

Plain film

Well-defined expansible lytic lesions with thin sclerotic margins

CT

Better assessment of cortical disruption and soft tissue extension

May demonstrate fluid-fluid levels

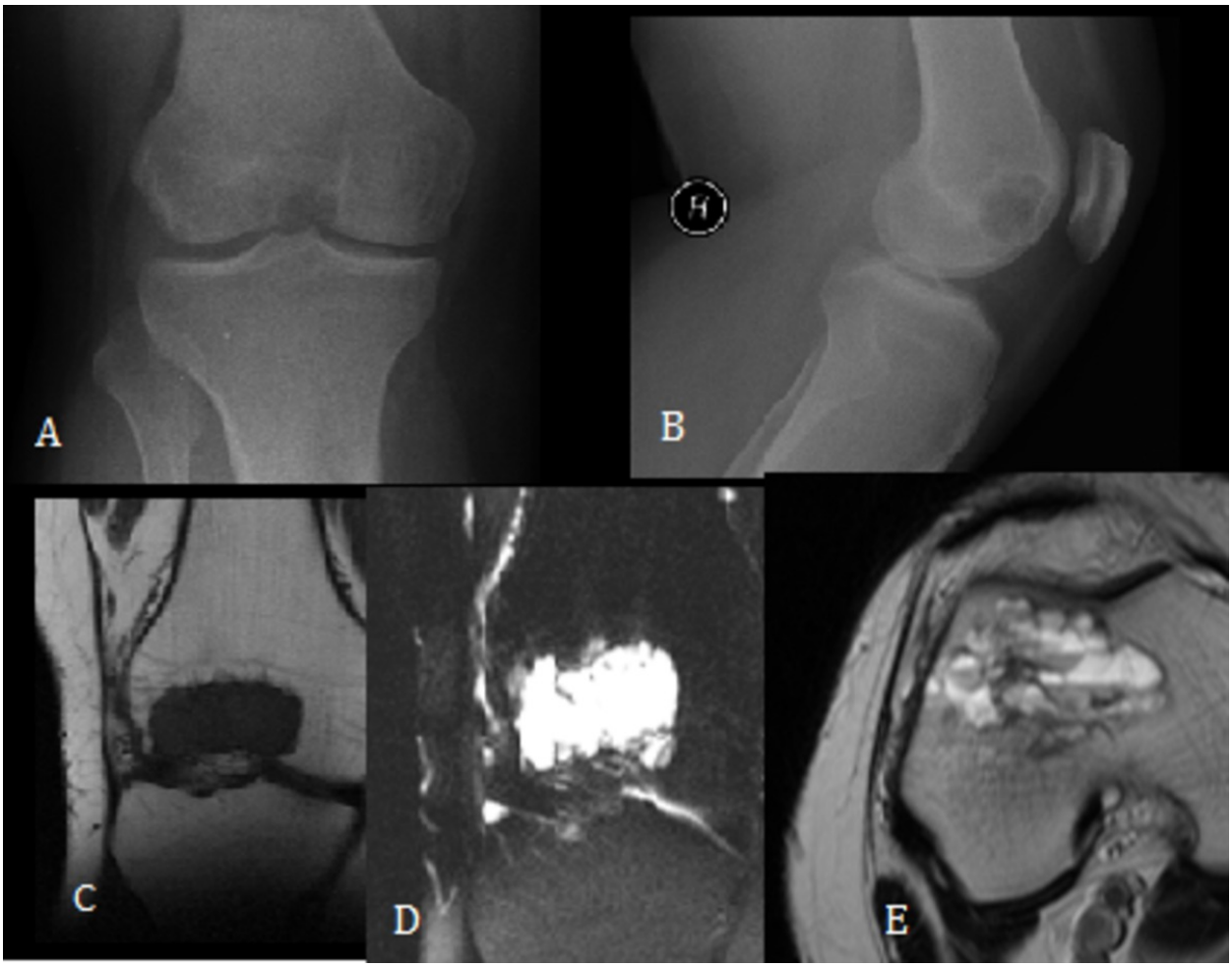

Fig. 16: Aneurysmal bone cyst. Frontal (A) and lateral (B) radiographs reveal a well-defined lytic lesion with sclerotic rim located in the central epiphysis with lateral extension. Coronal T1 weighted image (C), coronal fat suppression T2-weighted image (D) and axial T2 without fat supression weighted image (E) reveal a well-defined oval lesion in the epiphysis of the right femur. The lesion has a multiloculated appearance with fluid-fluid levels on T2-weighted images. It appears hypointense on T1 weighted images. No solid component, bone oedema or soft tissue mass associated
References: Serviço de Imagem Médica, Centro Hospitalar e Universitário de Coimbra, Faculdade de Medicina de Coimbra Medical Imaging Department and Faculty of Medicine, University Hospital of Coimbra, Portugal

MRI

This lesion exhibits low to intermediate signal intensity, with or without fluid levels, on T1-weighted images. Areas of high signal intensity on T1-weighted images may translate acute haemorrhage.

On T2- weighted images are seen areas of low to intermediate signal intensity or some areas of heterogeneous high signal intensity, depending on the contents of the cyst.

Surrounding rim of low signal intensity on both sequences

Better assessment of fluid-fluid levels

Reveal the presence of a solid component - secondary aneurysmal bone cyst

Tumor enhancement after contrast administration - secondary aneurysmal bone cyst?

Although fluid-fluid levels are characteristic of aneurysmal bone cyst they may occur in other lesion like Giant cell tumours, Chondroblastoma, Simple Bone cyst and Telangiectatic Osteosarcoma.

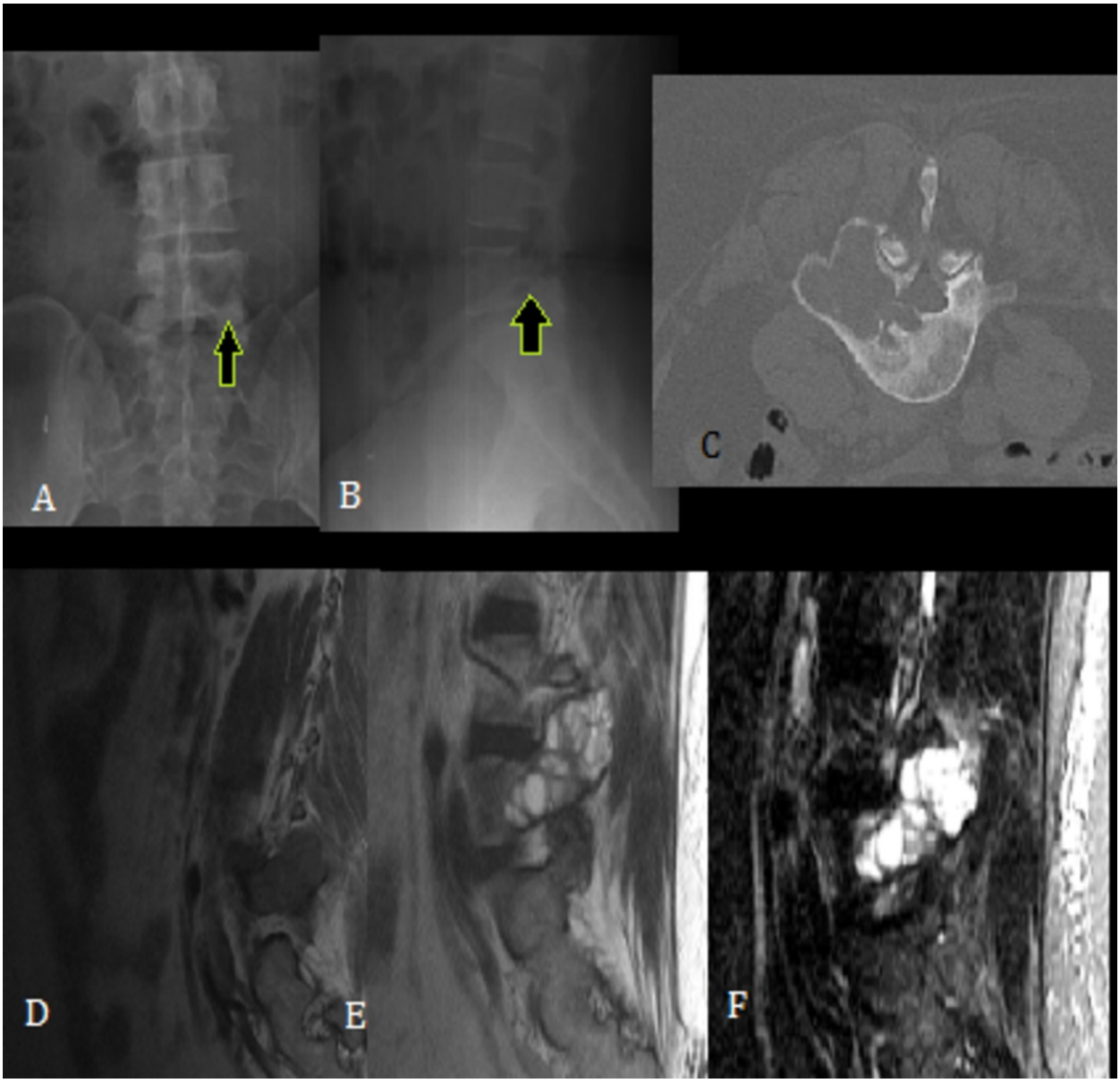

Fig. 17: Aneurysmal Bone cyst. Frontal and lateral radiographs (A, B) reveals a sharply demarcated lytic lesion in the left hemi body of the fifth lumbar vertebra (arrow). Axial computed tomography reformation image (C) shows a large expansible lytic lesion involving the left hemi body and posterior elements, without any evidence of

periosteal reaction and with cortical disruption. Sagittal T1 and T2 weighted images (D,E), sagittal T2 turbo inversion recovery weighted image (F) show a lesion located in the pedicle, transverse apophasis and body of the fifth lumbar vertebra. The lesion expands beyond the bony limits and has a small endocanalar component without frank compression of the dural sac. This lesion presents a multiloculated appearance, with fluid-fluid levels and highly heterogeneous signal intensity on T2-weighted images and low intensity of signal on T1 weighted images.

References: Serviço de Imagem Médica, Centro Hospitalar e Universitário de Coimbra, Faculdade de Medicina de Coimbra Medical Imaging Department and Faculty of Medicine, University Hospital of Coimbra, Portugal

Bone scan

Increased peripheral uptake with photopenic centre - Doughnut sign (nonspecific)

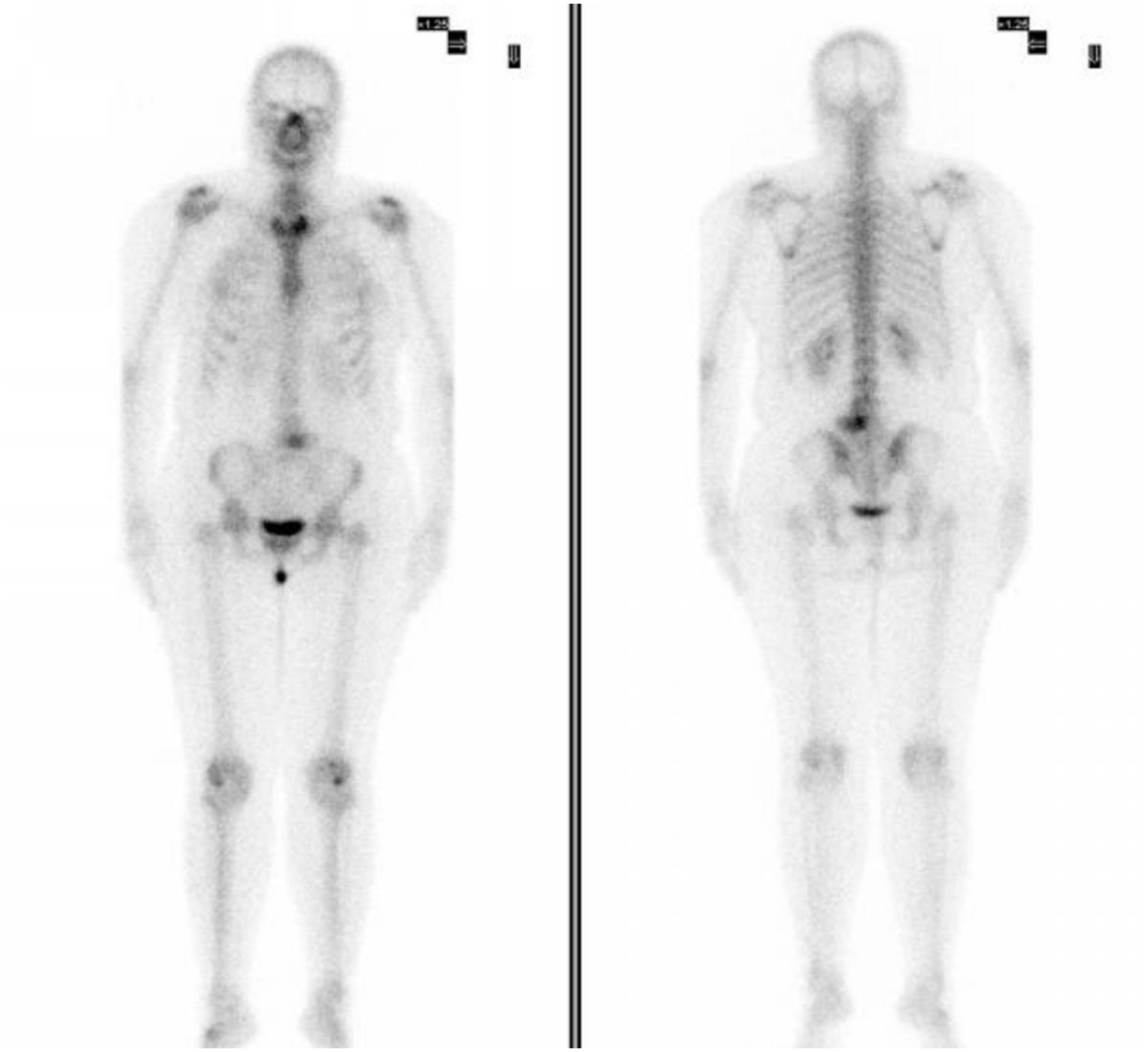

Fig. 18: Aneurysmal bone cyst. Bone scan (Same patient in figure 16) reveals increased osteoblastic activity with associated hyperaemia on the left side of the fifth lumbar vertebra.
References: Serviço de Imagem Médica, Centro Hospitalar e Universitário de Coimbra, Faculdade de Medicina de Coimbra Medical Imaging Department and Faculty of Medicine, University Hospital of Coimbra, Portugal

The differential diagnosis depends mostly on the image modality. Most of the mnemonic FEGNOMASHIC lesions are included in the differential diagnosis in conventional radiology and in a lesser degree in CT scans. When the age of the patient, location of the lesion, plain appearance and MRI appearance is taken to account the main differential diagnosis is made with fluid-fluid level lesions and with the most frequent underlying lesion (secondary aneurysmal bone cyst).

The standard treatment remains in controversy due to the high rate of recurrence (5-40%), regardless of technique applied. The principal techniques used are curettage and insertion of bone graft or bone cement.

Solitary Bone Cyst

Solitary bone cyst, also known as simple bone cyst or unicameral bone cyst is a true cyst. However they are not necessarily unicameral, with estimated incidence at 3% of all bone lesions.

They affect mostly young patients, generally under 30 years old, with a male to female ratio of 2 to 1.

Although it usually involves the proximal humerus and femur (>60%) and it is located in the central portion of the bone, it can occur in any bone. It is not commonly found around the knees. Frequently they are less expansible lesion when compared with aneurismal bone cyst. May present with fracture and a fallen fragment.

In the absence of fracture the patients are asymptomatic. Periosteal reaction is very uncommon even with pathologic fractures.

The cysts contain clear serous fluid surrounded by a fibrous membrane. The aetiology of these lesions is poorly understood. It is thought to originate from a defect during bone growth that fills up with fluid, leading to expansion and thinning of the surrounding bone. In the active phase the cyst remains near the growth plate, and as the lesion progresses to inactivity it migrates into the shaft of the bone.

Plain film

Well-defined, with narrow transitional zone, lytic lesions with no periosteal reaction

There can be bone expansion and thinning of the overlying bone.

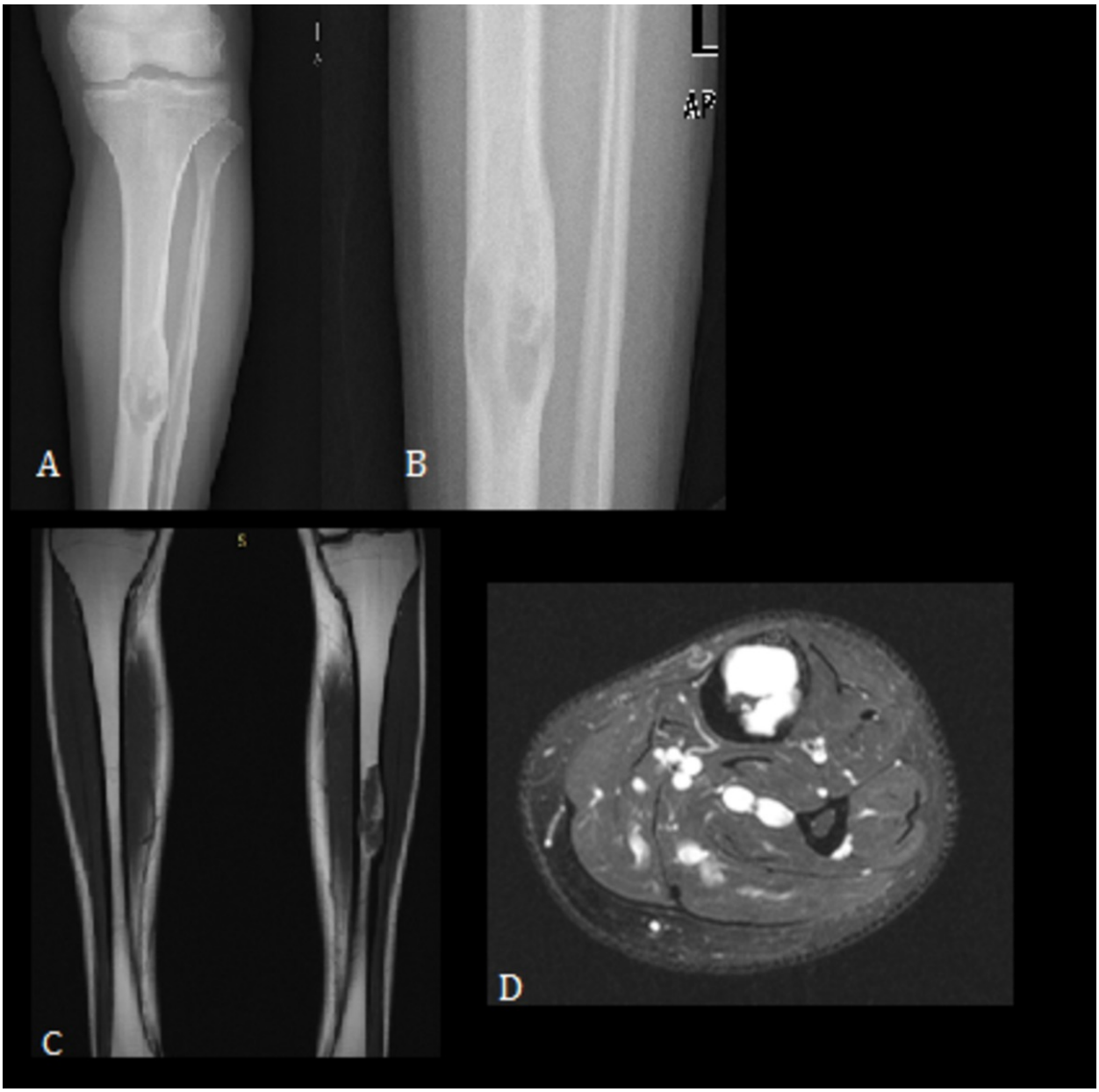

Fig. 19: Solitary bone cyst. Anterior-posterior (A) and lateral radiographs (B) reveal bone expansion with cortical thinning adjacent to a well-defined lytic lesion located in the middle third of the left tibia.Coronal T1 weighted image (C) axial T2 FS weighted image (B) show a intramedullary lesion located in the middle third of the left tibia with bone expansion and thinning of the adjacent cortical without disruption. This lesion has multiloculated areas with low signal intensity on T1 and high signal intensity on T2 weighted images.C

References: Serviço de Imagem Médica, Centro Hospitalar e Universitário de Coimbra, Faculdade de Medicina de Coimbra Medical Imaging Department and Faculty of Medicine, University Hospital of Coimbra, Portugal

Multiloculated appearance may be caused by prominent ridges of bone.

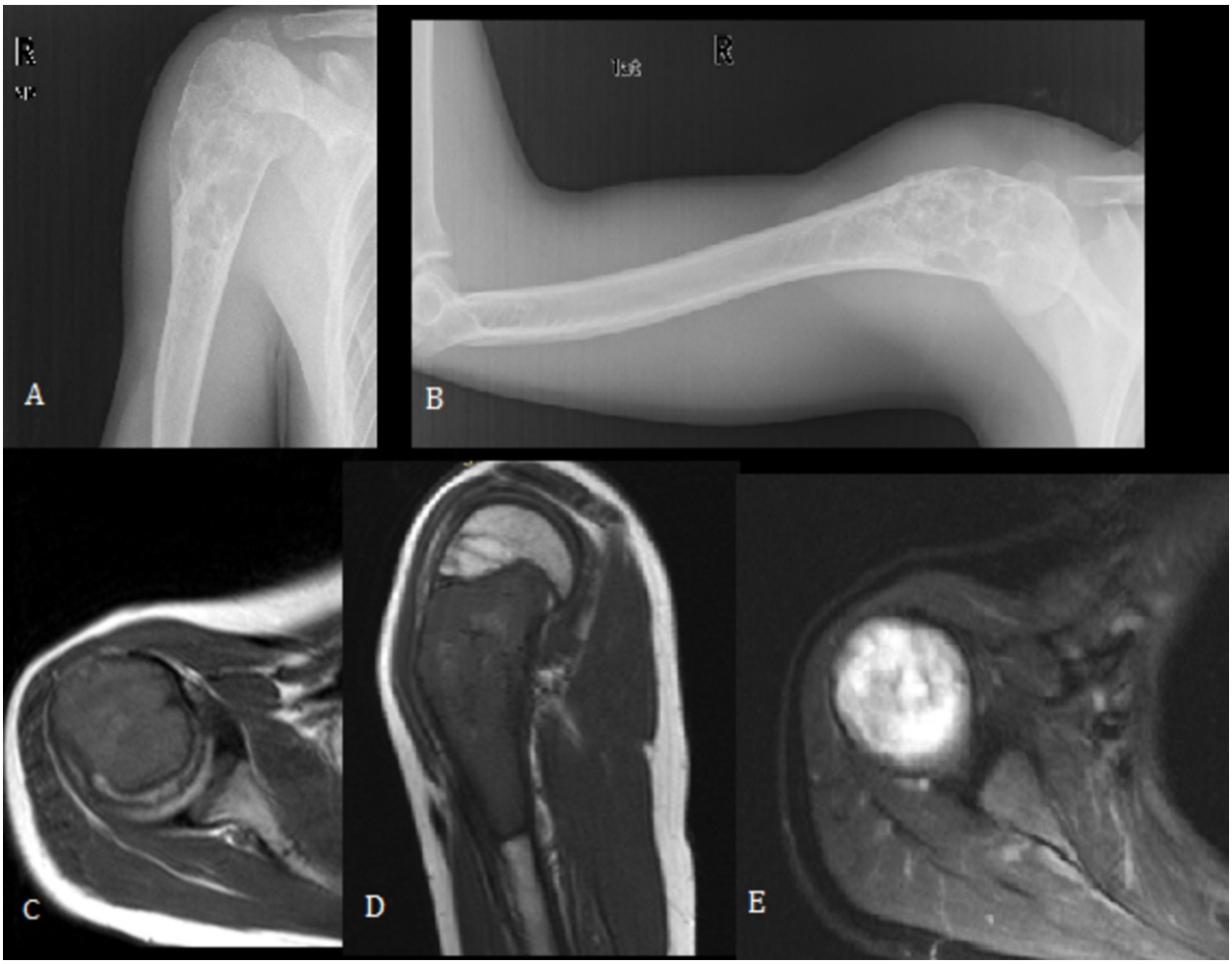

Fig. 20: Solitary bone cyst. Anterior-posterior (A) and lateral (B) radiographs of the left humerus shows an expansible medullary, radiolucent lesion in the proximal humeral metaphysis extending to the growth plate is seen. T1 axial and sagittal (C, D) weighted image and T2 fs weighted image (E) reveal a hypointense on T1 weighted image with areas of hyperintensity on T2 weighted images lesion.
References: Serviço de Imagem Médica, Centro Hospitalar e Universitário de Coimbra, Faculdade de Medicina de Coimbra Medical Imaging Department and Faculty of Medicine, University Hospital of Coimbra, Portugal
Uncommonly they are truly multiloculated.

Dependent bony fragment associated with fracture - fallen fragment sign.

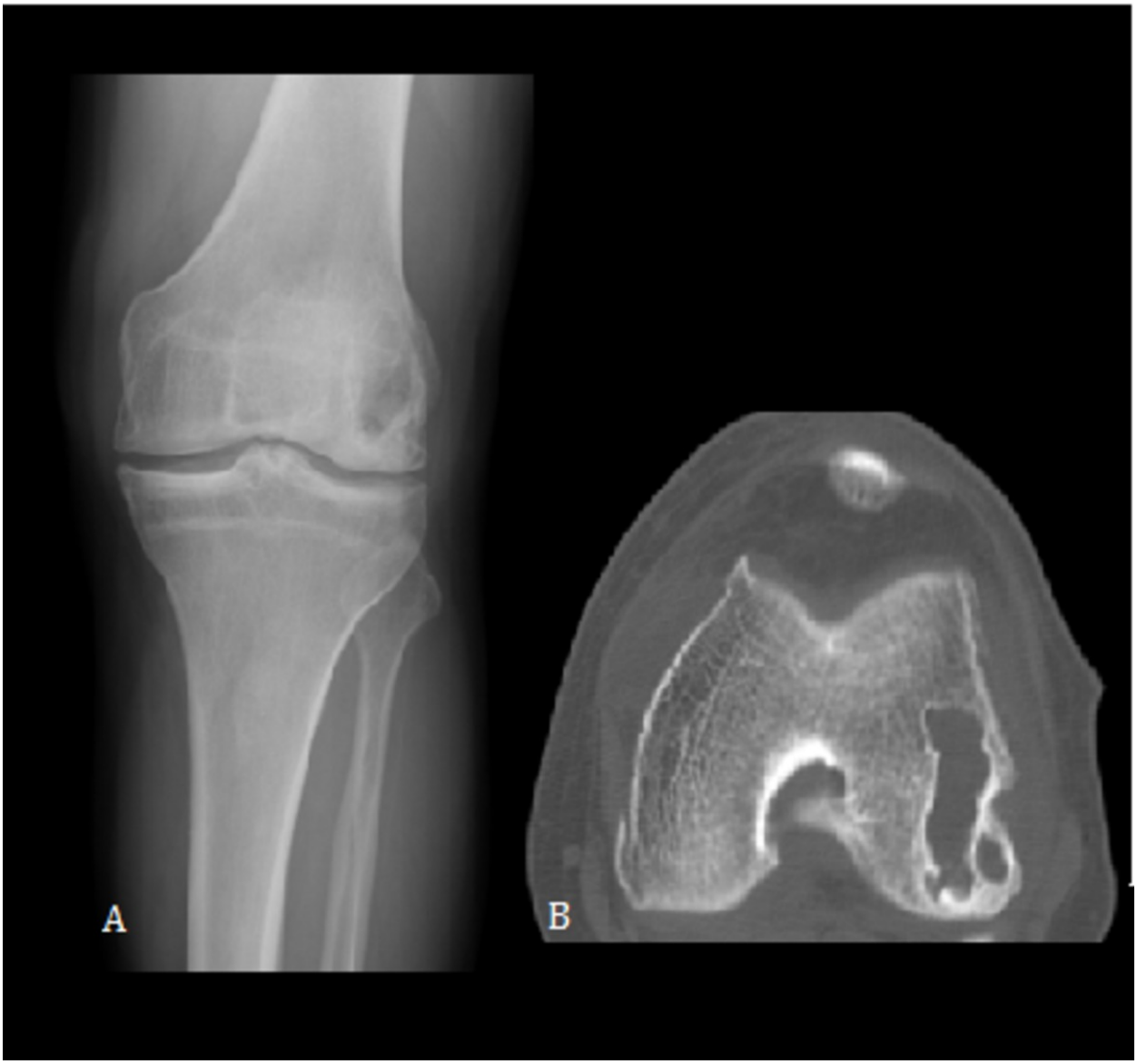

Fig. 21: Solitary bone cyst. Anterior-posterior radiography (A) of the left knee reveals a small sharply marginated lesion located in the lateral condyle. Axial computed tomography reformation (B) show a well-defined lesion, with sclerotic rim and multilocated appearance caused by prominent ridges of bone.
References: Serviço de Imagem Médica, Centro Hospitalar e Universitário de Coimbra, Faculdade de Medicina de Coimbra Medical Imaging Department and Faculty of Medicine, University Hospital of Coimbra, Portugal

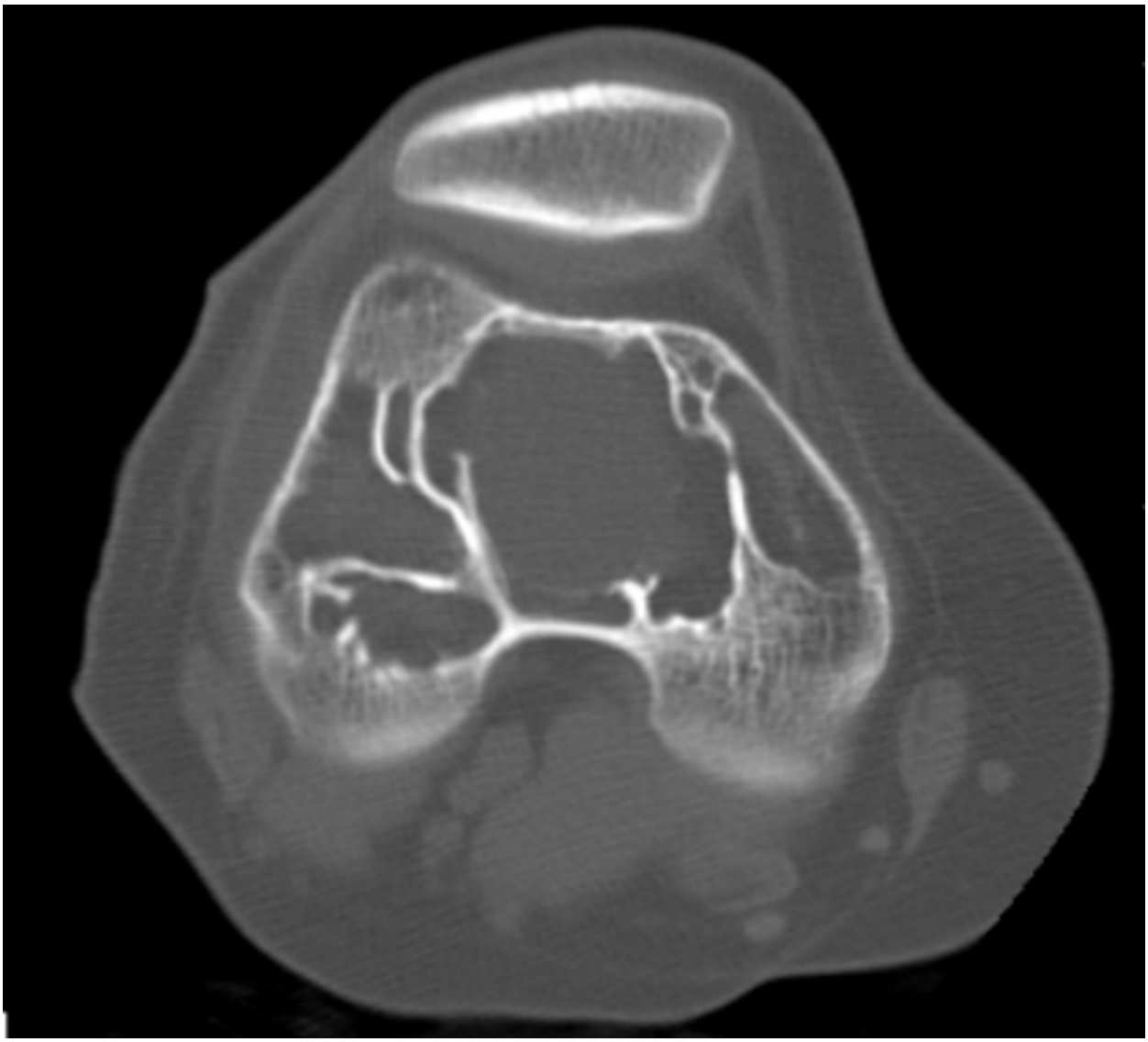

Fig. 22: Solitary bone cyst. Axial computed tomography reformation of the right femoral bone reveals a multiloculated appearance well-defined lytic lesion.
References: Serviço de Imagem Médica, Centro Hospitalar e Universitário de Coimbra, Faculdade de Medicina de Coimbra Medical Imaging Department and Faculty of Medicine, University Hospital of Coimbra, Portugal

CT & MRI

Help to distinguish the simple bone cyst from other mimicking lesion.

The uncomplicated lesion has low signal intensity on T1 weighted images and high signal intensity on T2 weighted images.

Fluid-fluid levels are only present when the lesion is complicated with haemorrhage.

No kind of intervention is usually required for asymptomatic lesion. When the cyst is large with a higher probability of fracture or causes deformity, an intra-lesional steroid injection can be performed. If the cyst is complicated with a fracture, it frequently heals without any treatment. In fewer cases, surgery with curettage and bone grafting is necessary.

The differential diagnosis should be made with aneurysmal bone cyst, giant cell tumour, non-ossifying fibroma, eosinophilic granuloma and fibrous dysplasia.

Hyperparathyroidism (Brown Tumor)

Brown tumor is a non-neoplastic lesion. It is considered as a reparative granulomas without malignant or neoplastic potential.

Brown tumors are rare sequelae of hyperparathyroidism, with a slightly greater frequency in primary than in secondary hyperparathyroidism. The majority of patients with brown tumours have secondary hyperparathyroidism as secondary hyperparathyroidism is much frequent than primary hyperparathyroidism.

This tumour can manifest itself at any age, but it is more common among people over 50 years old. It is also three times more common in women than in men.

The majority of patients with hyperparathyroidism are asymptomatic. Hypercalcemia, hypophosphatemia and increased alkaline phosphatase levels are often incidentally discovered in routine blood tests.

This lesion may be the first finding of hyperparathyroidism. It can affect any bone, the most common sites of involvement being facial bones, pelvis, ribs and femoral bone.

In localized bone regions occurs rapid bone reabsorption the normal marrow can be replaced with a variable amount of haemorrhage, reparative granulation tissue, and proliferating fibrous tissue.

Other manifestations of hyperparathyroidism are frequently present. They include osteopenia, subperiosteal and subcondral bone reabsorption, intracortical tunnelling, chondrocalcinosis and para-articular and vascular calcifications.

Plain film

Variable appearance - well to poorly defined lytic lesion to a sclerotic process.

Septa and bone expansion may be seen.

Often eccentric/cortical lesion

Frequently solitary lesion

CT

Attenuation values on CT will be in the range of blood and fibrous tissue.

MRI

The imaging characteristics depend on the relative proportion of fibrous tissue, haemorrhage, and cystic components. The lesions may be solid, cystic, or mixed. Solid components are intermediate to low intensity on T1- and T2-weighted images, while the cystic components are hyperintense on T2-weighted images and may have fluid-fluid levels. The solid components and septae may enhance after contrast administration.

Bony expansion can be visualized and helps to determinate the extent of the lesion. Lack of an associated soft-tissue mass is a pertinent negative finding that can be demonstrated on MRIs.

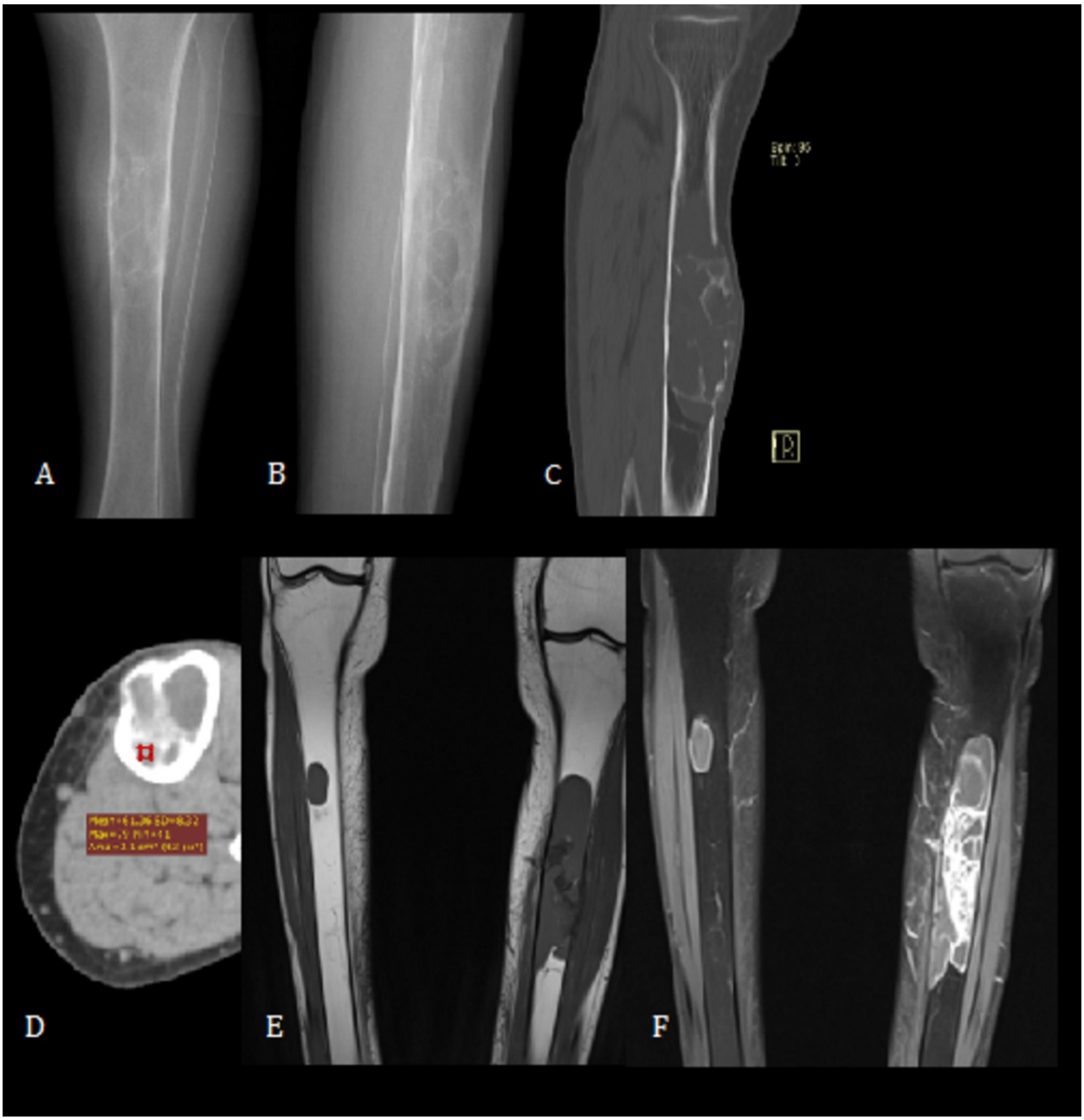

Fig. 23: Hyperparathyroidism - Brown Tumors.Anteroposterior radiography (A) and Lateral radiography (B) show an eccentric expansive lytic well-marginated lesion with multiple septae in the left tibial diaphysis. Sagittal (C)and axial (D)computed tomography reformations show an expansive lesion with multiple septae with attenuation values of blood. Coronal T1 weighted image (D) and Coronal T1 FS after gadolinium administration (E) reveal a large eccentric hypointense well-defined lesion affecting the left tibial diaphysis and a smaller cortical lesion located in the right tibial diaphysis. Absence of soft tissue expansion.

References: Serviço de Imagem Médica, Centro Hospitalar e Universitário de Coimbra, Faculdade de Medicina de Coimbra Medical Imaging Department and Faculty of Medicine, University Hospital of Coimbra, Portugal

Angiography

Usually hypervascular lesion

Bone scan

Often shows intense uptake.

The differential diagnosis depends of the location of the lesion, age, and the presence or absence of other signs of hyperparathyroidism, including aneurismal bone cyst, metastases and giant cell tumor.

The treatment of choice for primary hyperparathyroidism is parathyroidectomy. However there is not a consensus regarding treatment of brown tumours. Most authors recommend initial treatment with systemic corticosteroids, followed by surgical removal of residual brown tumor. Nonetheless, in cases of large cystic lesions with low probability of remodelling after adequate metabolic control, and persisting lesion after six months with or without growth with normocalcemia, it is recommend curettage and enucleation.

Infection - Osteomyelitis

Osteomyelitis refers to bone inflammation due to infection. It can occur at any age group, mostly in the male gender. Frequently results from haematogeneous spread, although direct extension is also relatively frequent. Staphylococcus aureus is the most common agent.

The location of this condition varies with age of the patient, frequently affecting the metaphysis and/or epiphysis of neonatas, the metaphysis of children ans the epiphysis and subcondral regions of adults.

There some specific apperances regarding osteomyelitis like subperiosteal abscess, Brodie's abscess, Pott's puffy tumour and sclerosing osteomyelitis of Garré.

Plain film

Loss of normal fat planes

Effusion - adjacent joint

Regional osteopaenia

Periosteal reaction / Periosteal thickening

Focal bony lysis

Endosteal scalloping

Peripheral sclerosis

In **chronic or untreated cases** - bone sequestrum/involucrum

CT

Better assessment of bone margins and sequestrum/involucrum.

MRI

Better assessment of soft-tissue/joint complications

It may present intermediate to low central component signal , with surrounding bone marrow lower signal, and enhancement of the bone marrow and the abcess periosteum margins on T1-weighted images. T2 weighted images may also demonstraste bone marrow oedema and fluid.

Nuclear medicine

With it`s different techniques may auxiliate the diagnosis and follow up.

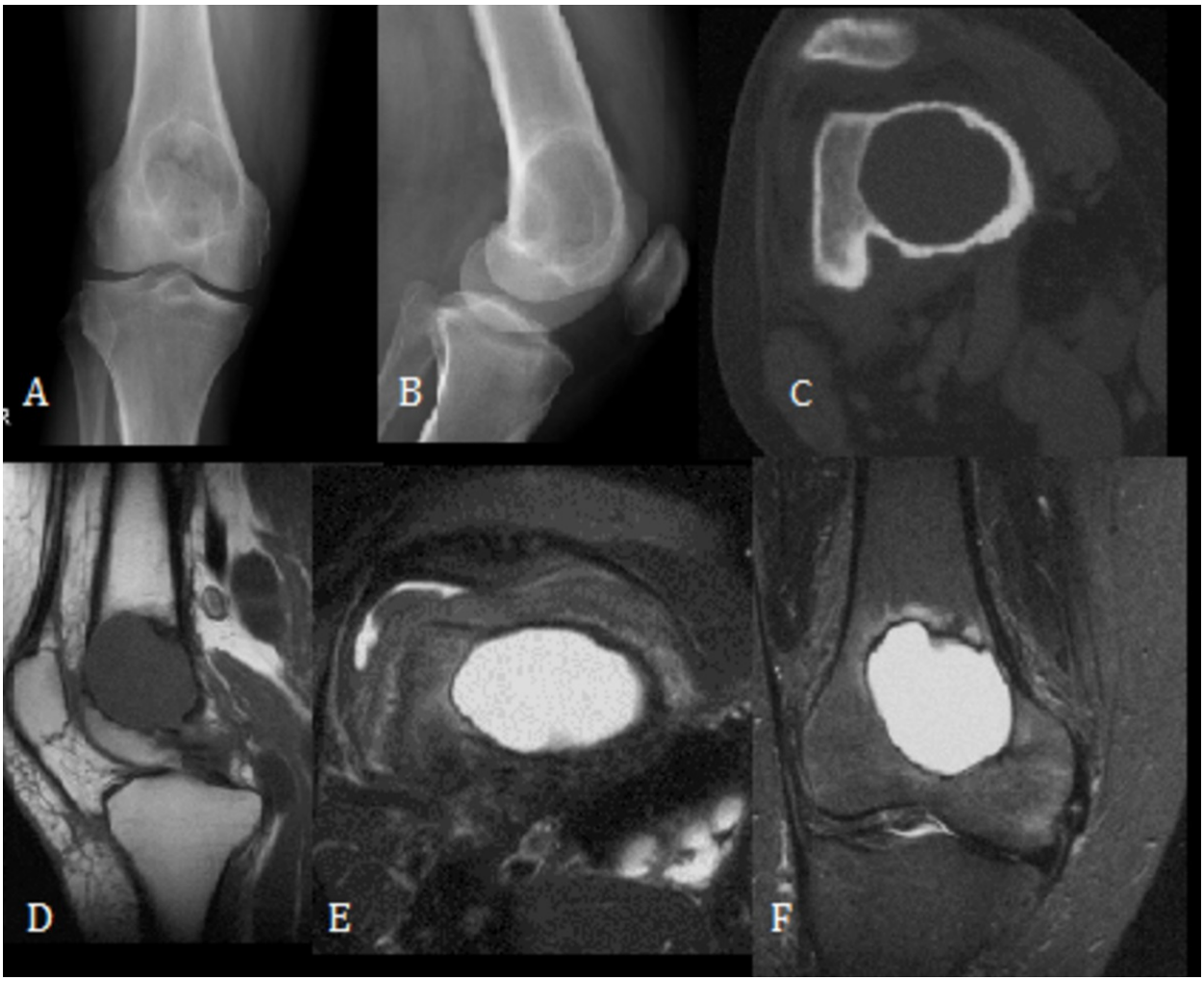

Fig. 24: Brodie's abscess. Frontal (B) and lateral (A) radiographs and axial computed tomography reformation (C) show a lytic lesion, with sclerotic margins located in medial malleolus of the right femur. Sagittal T1-eighted image (D), axial T2 and coronal T2 weighted images show a low intensity of signal, with surrounding lower bone marrow signal on T1-weighted images. T2 weighted images show a hyperintense lesion with surrounding bone marrow oedema.
References: Serviço de Imagem Médica, Centro Hospitalar e Universitário de Coimbra, Faculdade de Medicina de Coimbra Medical Imaging Department and Faculty of Medicine, University Hospital of Coimbra, Portugal

Unfortunately there is not a single radiologic aspect that sugest osteomyelites, therefore infection is amolst always present in the differential diagnosis of a lytic lesion.

Osteomyelites is generally treated with long-term intravenous antibiotics. If it is complicated with a collection, sequestrum or involucrum drainage and/or surgical debridement may be useful.

Chondroblastoma

Chondroblastoma is a rare benign cartilaginous tumor, with a strong predilection for the epiphysis of long tubular bones with an incidence of less than 1% of all bone tumours. Male predominance (sex ratio: 2 H / 1 F) associated with young age (5-25 year old).

Almost 75% of this tumour occurs in the epiphyses of long bones before skeletal maturity, like the humerus, femur, tibia, apophyses, pelvis, tarsus and patella.

Clinical presentation is not specific, generally with pain and restricted mobility.

Chondroblastoma is composed of chondroblasts, chondroid matrix and cartilage with few giant multi-nucleated cells.

A few cases of distant metastases and local and vascular invasion associated with chondroblastoma revealing a malignant behaviour have been described.

Plain film

Round or oval lytic lesion with sharp sclerotic margins

Calcifications - varying from amorphous pattern (+++) to punctate or rings-and-arc patterns.

It tends to have eccentric location within the epiphysis

Sometimes associated with solid periosteal reaction

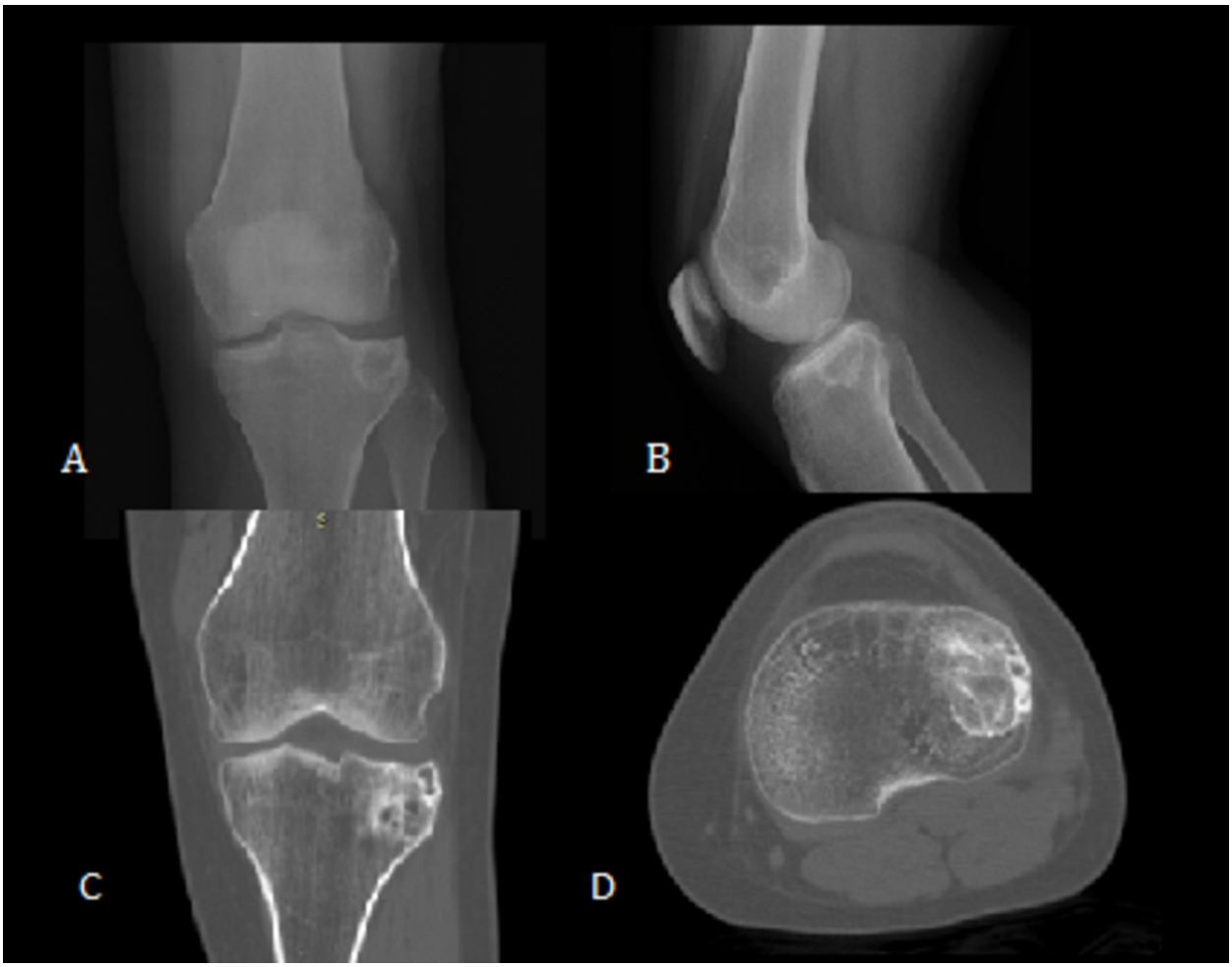

Fig. 25: Chondroblastoma. Anterior-posterior (A) e lateral (B) radiographs, Coronal (C) and axial (D) computed tomography reformations of the left knee reveal a well-demarcated lytic lesion in the proximal epiphysis of the left tibia,with chondroid matrix, surrounded by a thin sclerotic rim.
References: Serviço de Imagem Médica, Centro Hospitalar e Universitário de Coimbra, Faculdade de Medicina de Coimbra Medical Imaging Department and Faculty of Medicine, University Hospital of Coimbra, Portugal

Computed tomography

To assess the detection of matrix mineralization and of the sclerotic rim

MRI

Helps to assess the absence of a soft tissue component or intra-articular extension and it may also reveal bone marrow and adjacent soft tissue oedema.

The lesion is isointense with muscle on T1 weighted images and has heterogeneous intermediate to high signal intensity on T2-weighted images.

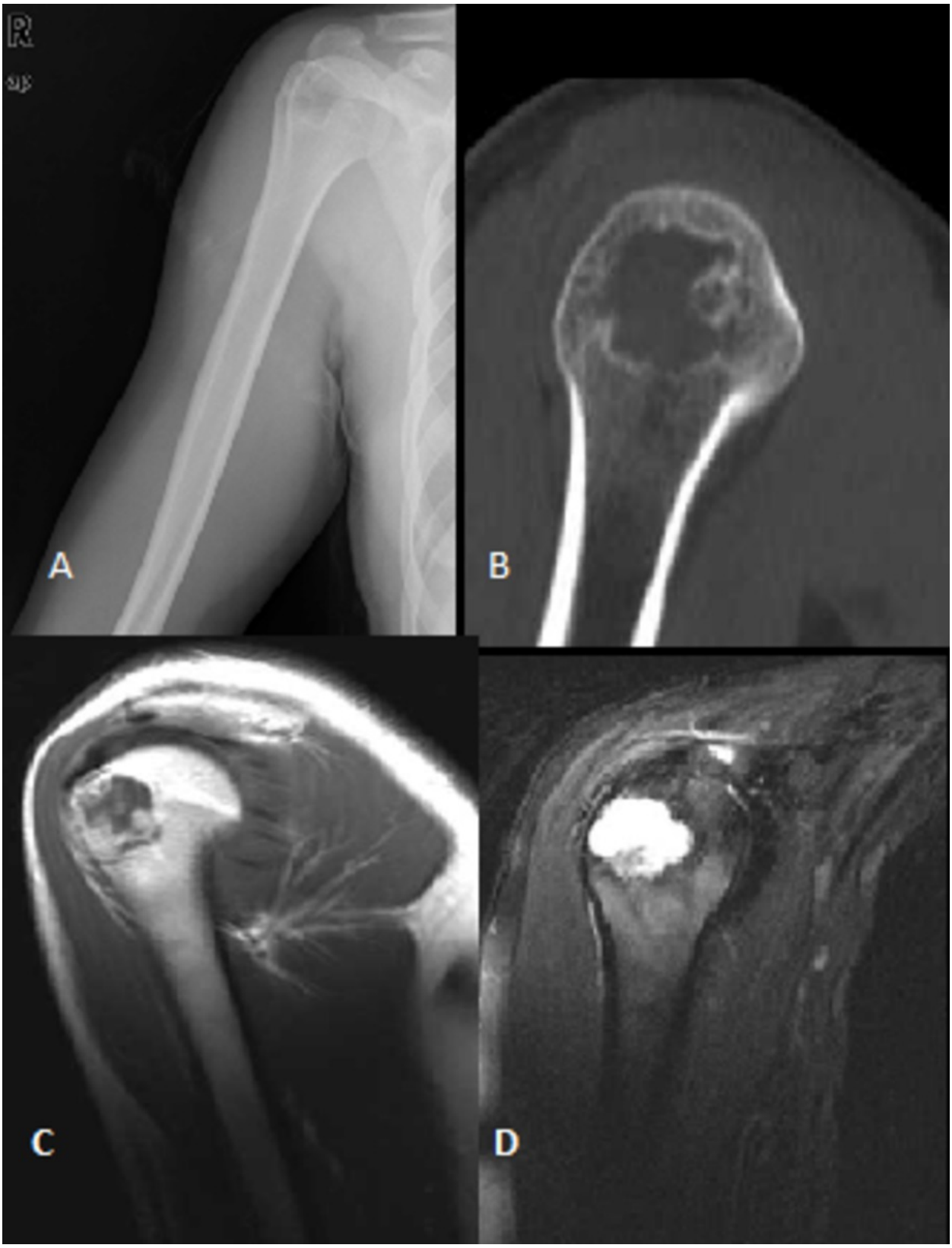

Fig. 26: Chondroblastoma: Anteroposterior (A) radiograph and sagittal (B) computed tomography reformation of the right arm show a well-demarcated lytic lesion in the

proximal epiphyseal humerus, surroundedby a thin sclerotic rim. Sagital T1- (C) and coronal fat-suppressed T2-weighted (D) images show a lobulated lesion in the proximal epiphyseal humerus. The lesion is isointense to muscle on T1-weighted image and shows heterogeneous high signal intensity on T2-weighted image. There is also bone marrow oedema.

References: Serviço de Imagem Médica, Centro Hospitalar e Universitário de Coimbra, Faculdade de Medicina de Coimbra Medical Imaging Department and Faculty of Medicine, University Hospital of Coimbra, Portugal

The differential diagnosis of an epiphyseal lesion in young patients (under 30 years old) is made with chondroblastoma, infection and giant cell tumour.

Surgery is the treatment option for this lesion. Curettage, either alone or with bone grafting, or packing the cavity with bone cement are the most common approaches. Radiofrequency ablation has also been used.

The proximity to the articular surface and growth plate makes complete resection difficult, resulting in a high rate of recurrence.

Chondromyxoid fibroma

Chondromyxoid fibroma is an extremely rare benign cartilaginous tumor and accounts for 0.5% of bone tumours.

It is more common in the second and third decades of life and has no gender predominance. It affects the metadiaphysis of long bones, mostly near the knee joint (60%). This lesion has a medullary eccentric location.

They manifest with progressive pain, often with long standing and/or bony swelling and restricted mobility in affected segment.

Chondromyxoid fibroma has a variable composition, a mixture of chondroid, myxoid, and fibrous tissue components organised in a pseudolobulated architecture.

Plain Film

Round or oval, well-defined, sharply marginated lytic lesion with peripheral sclerotic rim

Calcifications are usually not seen. When present, they can be seen in punctuate, occulent or ring-and-arcs patterns.

Computed tomography

Helps to assess the matrix calcification and the presence of a sclerotic rim

Magnetic resonance

The MRI findings are nonspecific. This condition exhibits low signal intensity on T1-weighted images and heterogeneous high signal intensity on T2-weighted images.

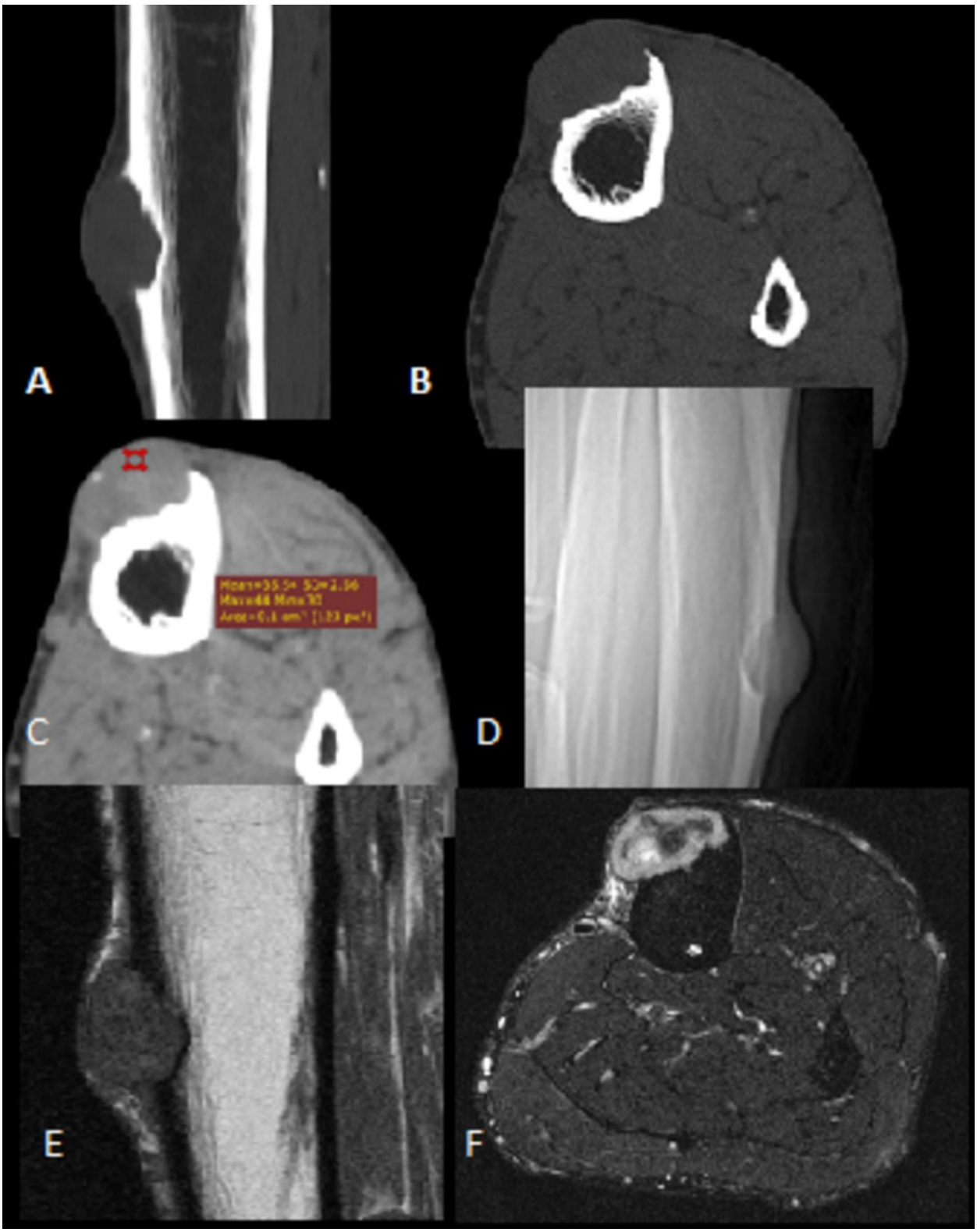

Fig. 27: Chondromyxoid fibroma. MPR thick (A) and axial computed tomography reformations (B, C) show an eccentric well-defined lytic lesion, with chondroid matrix, and a punctate calcification in the left tibia. The computed tomography orientation scout (D) reveals an oval, well-defined, sharply marginated eccentric lytic lesion in the left tibia.Sagittal T1 weighted image (E) and axial T2 weighted image (F) reveals a low signal intensity eccentric lesion on T1-weighted images and with heterogeneous high signal intensity on T2-weighted images located.
References: Serviço de Imagem Médica, Centro Hospitalar e Universitário de Coimbra, Faculdade de Medicina de Coimbra Medical Imaging Department and Faculty of Medicine, University Hospital of Coimbra, Portugal

The differential diagnosis is made mainly with non-ossifying fibroma, aneurysmal bone cyst, giant cell tumour of bone and chondroblastoma.

Malignant degeneration of chondromyxoid fibroma is very rare. Curettage is a frequent option, although it is associated with a high recurrence rate. When possible an en-bloc resection is advised.

Images for this section:

R
90

Fig. 1: Fibrous dysplasia. Frontal radiography of the right knee shows a well-defined lesion with sclerotic margins and hazy matrix in femoral diaphysis.

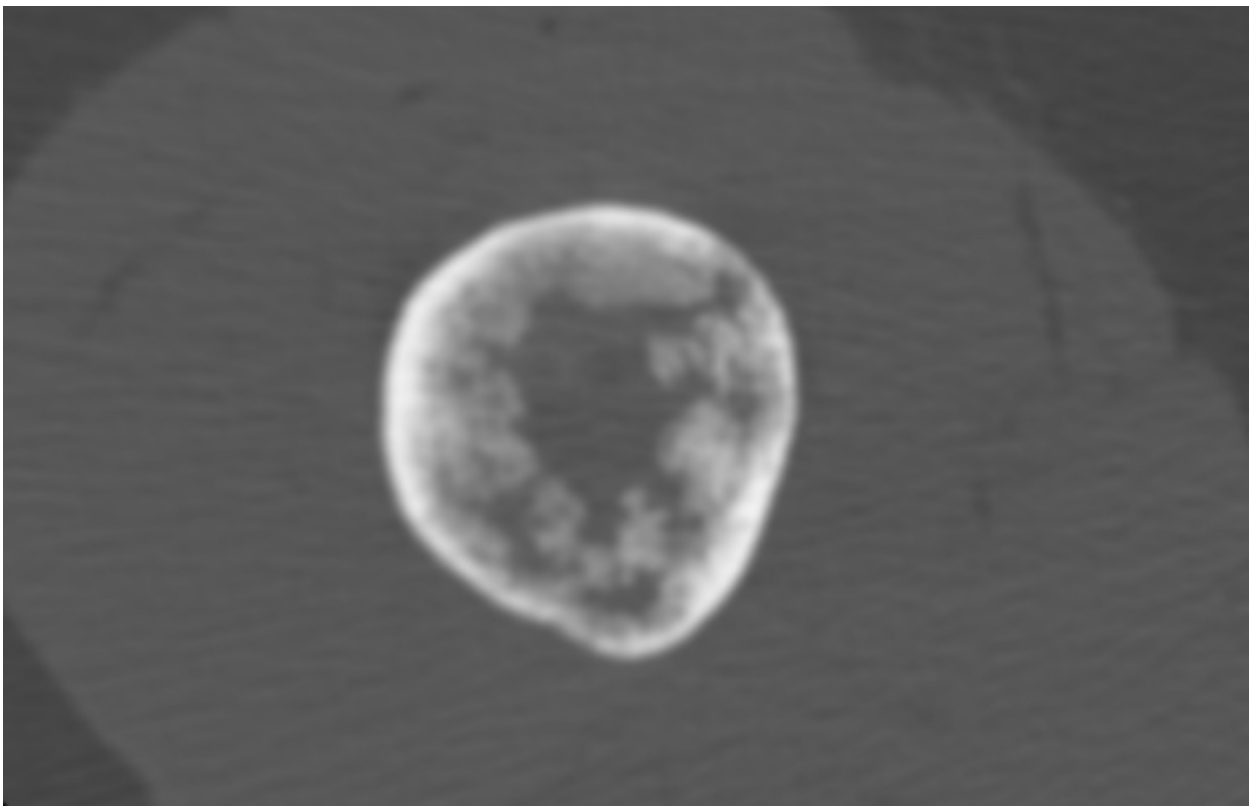

Fig. 2: Fibrous dysplasia. Axial computed tomography reformation image (B) of the same patient in figure 1.

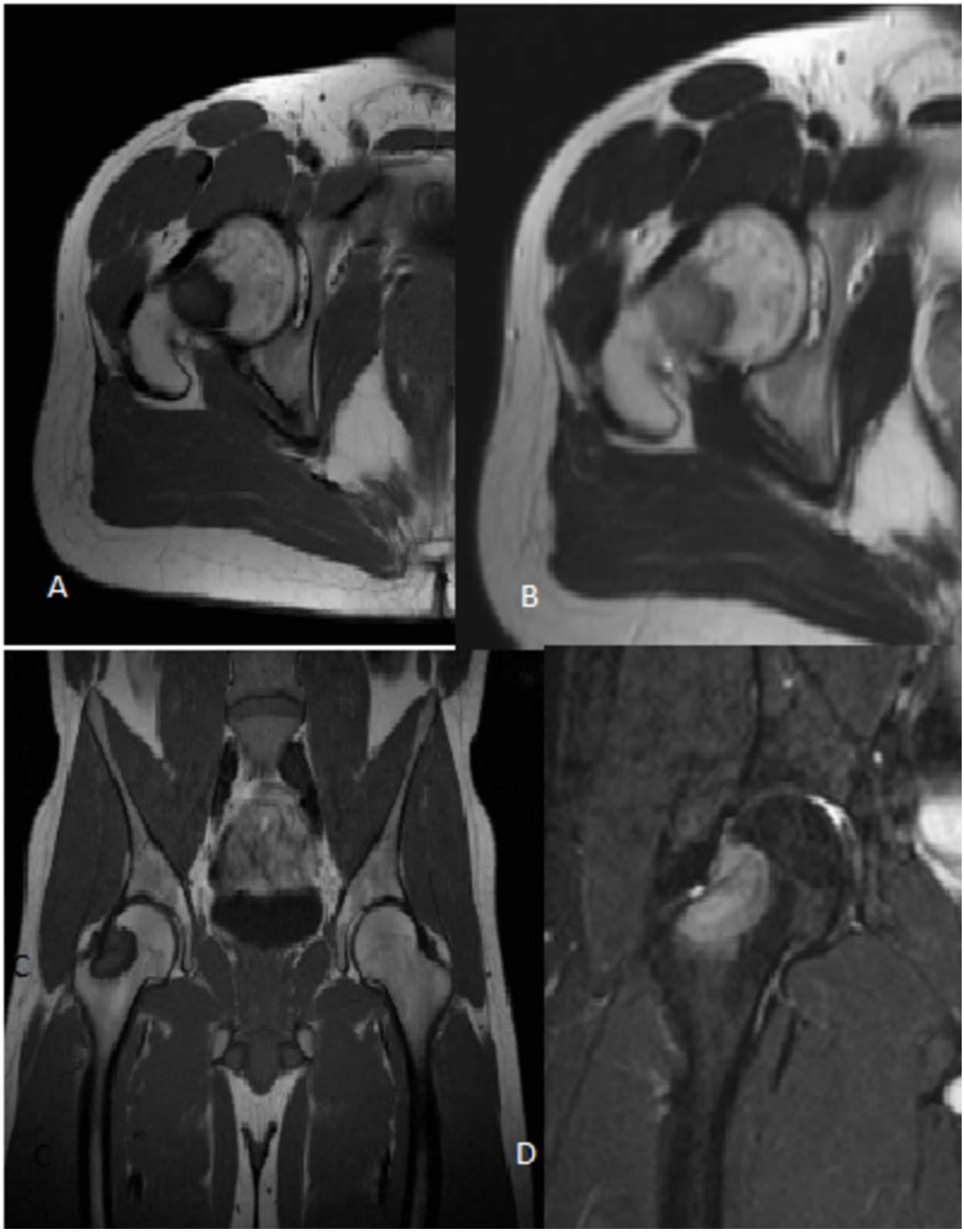

Fig. 3: Fibrous Dysplasia. Axial T1-weighted image, axial T2-weighted image. coronal T1 and T2-weighted without fat supression image reveal a small lesion in the right femoral

neck. It presents with low signal intensity (A, C) and interme diate intensity of signal on T2-weighted image (B, D).

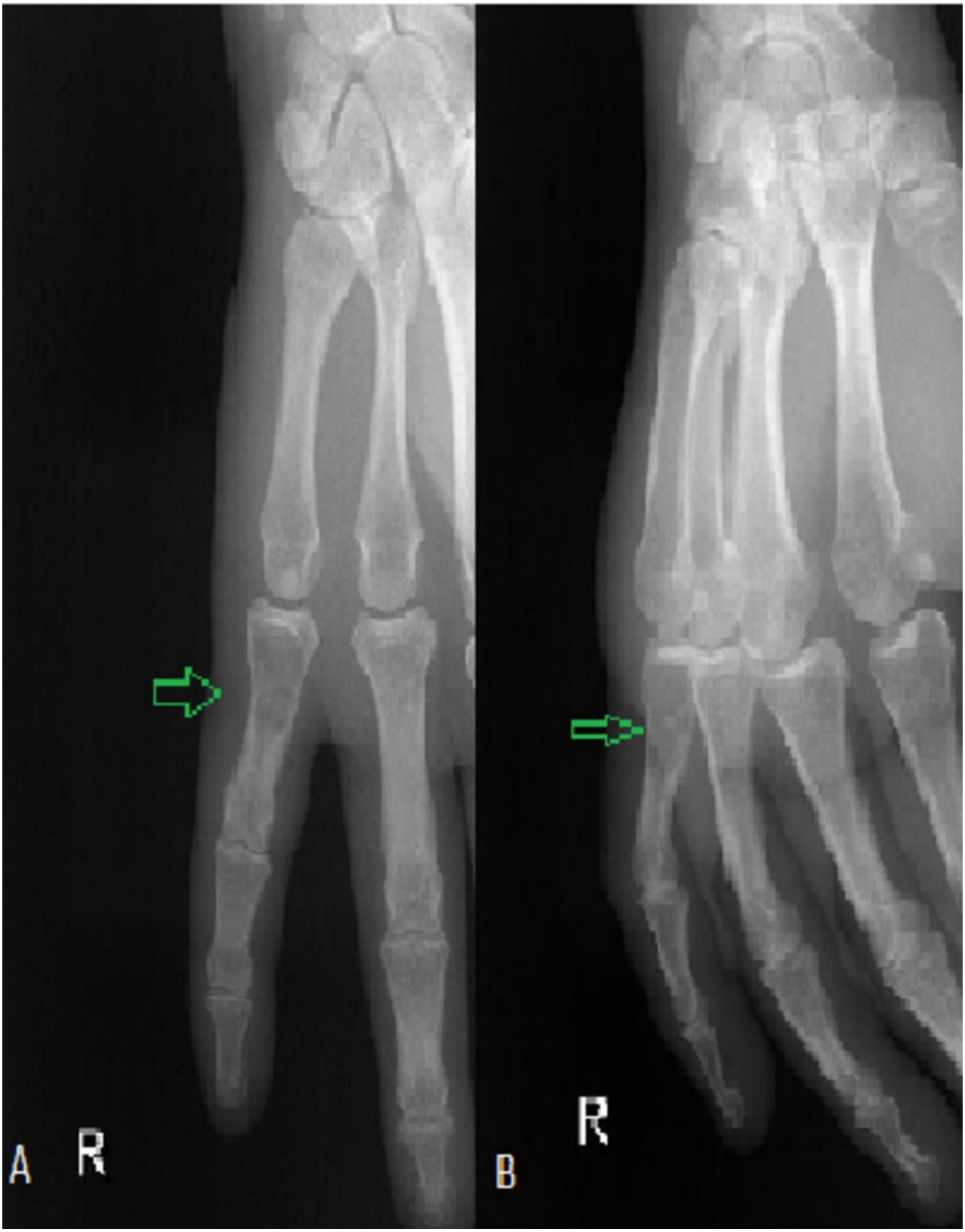

Fig. 4: Enchondroma. Anterior-posterior and lateral radiographs of the right hand reveals a well-defined lytic lesion located in the proximal phalange of the fifth finger (arrow).

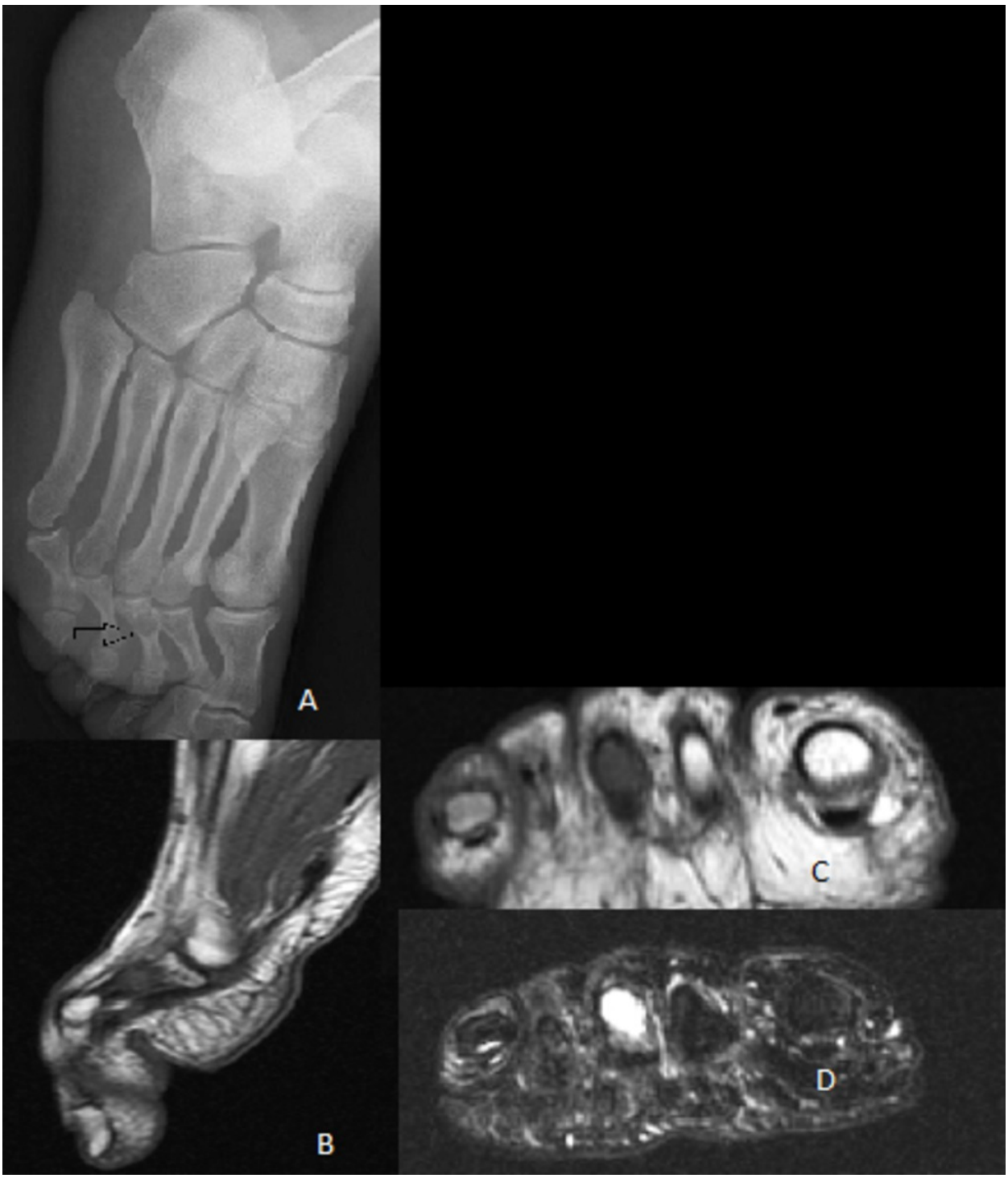

Fig. 5: Enchondroma. Oblique (a) radiography of the right foot show a well-defined lytic lesion, with a thin sclerotic border, in the proximal phalange of the third finger(arrow). T1 sagittal (B) and transverse (C) weighted images show a hypointense endomedular lesion in the proximal phalange of the third finger. The T2 transverse weighted image

(D) reveals a hyperintense lesion in the same location. There is no soft tissue mass or invasion of the metacarpo-phalangeal joint associated.

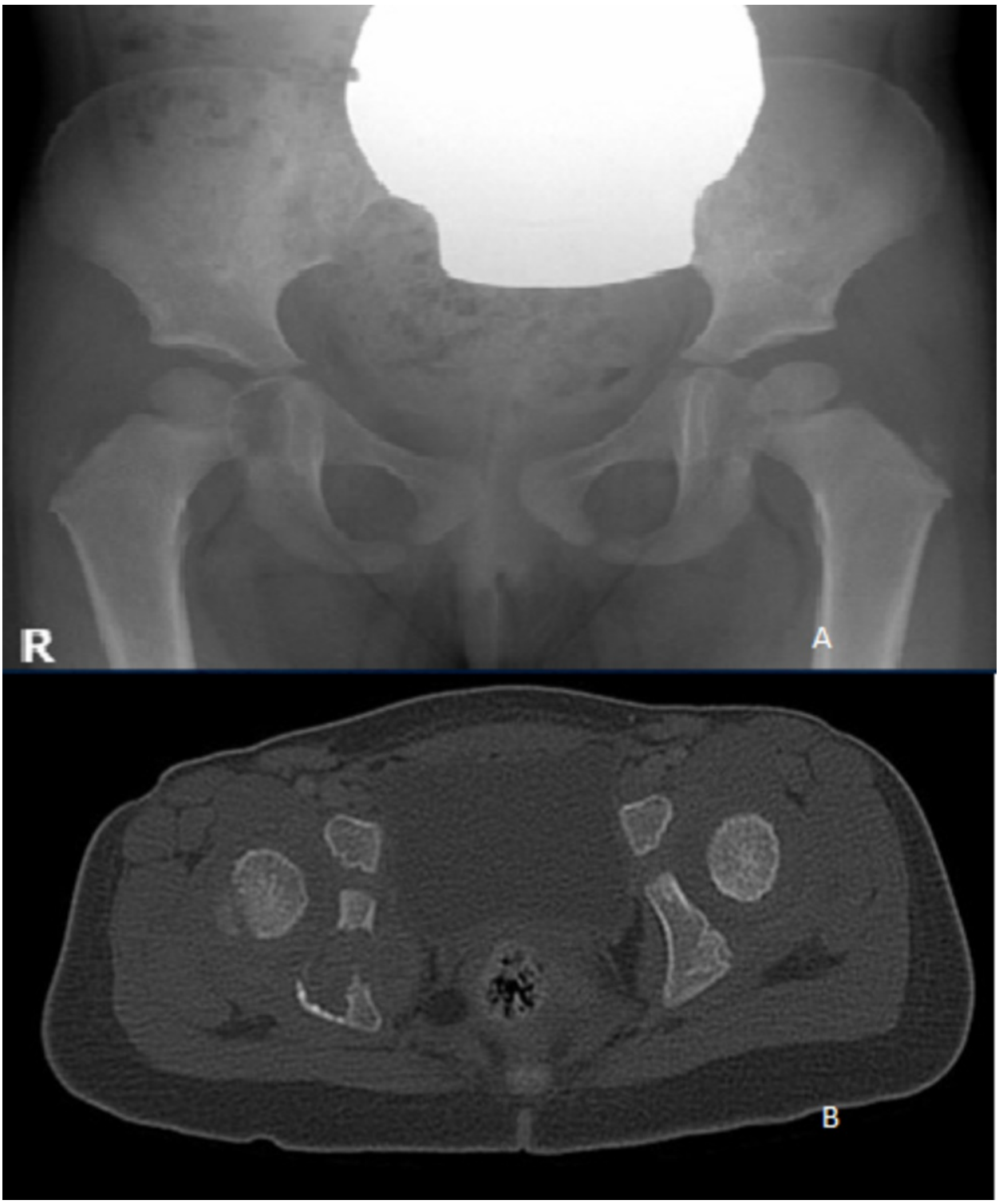

Fig. 6: Eosinophilic granuloma. Frontal radiography (A) shows a large well-defined lytic lesion in the right pelvic bone. Axial computed tomography (B) of the same patient reveals a large lytic lesion located in the right pelvic bone with cortical disruption.

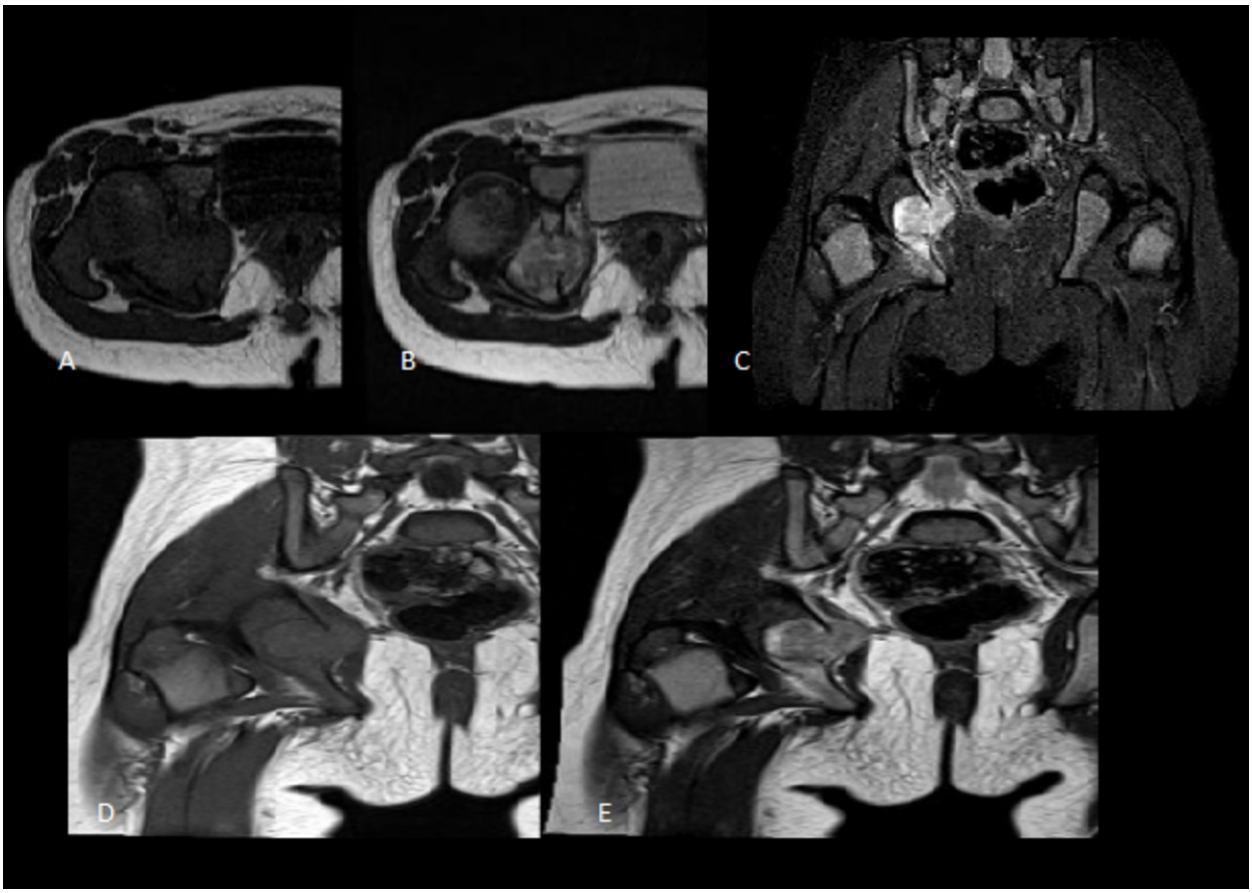

Fig. 7: Eosinophilic granuloma. This lesion presents with low intensity of signal on T1-weighted images (A,D) and slightly heterogeneous hyperintensity signal on T2-weighted images (B,E). There is bone marrow and surrounding muscle oedema (C).

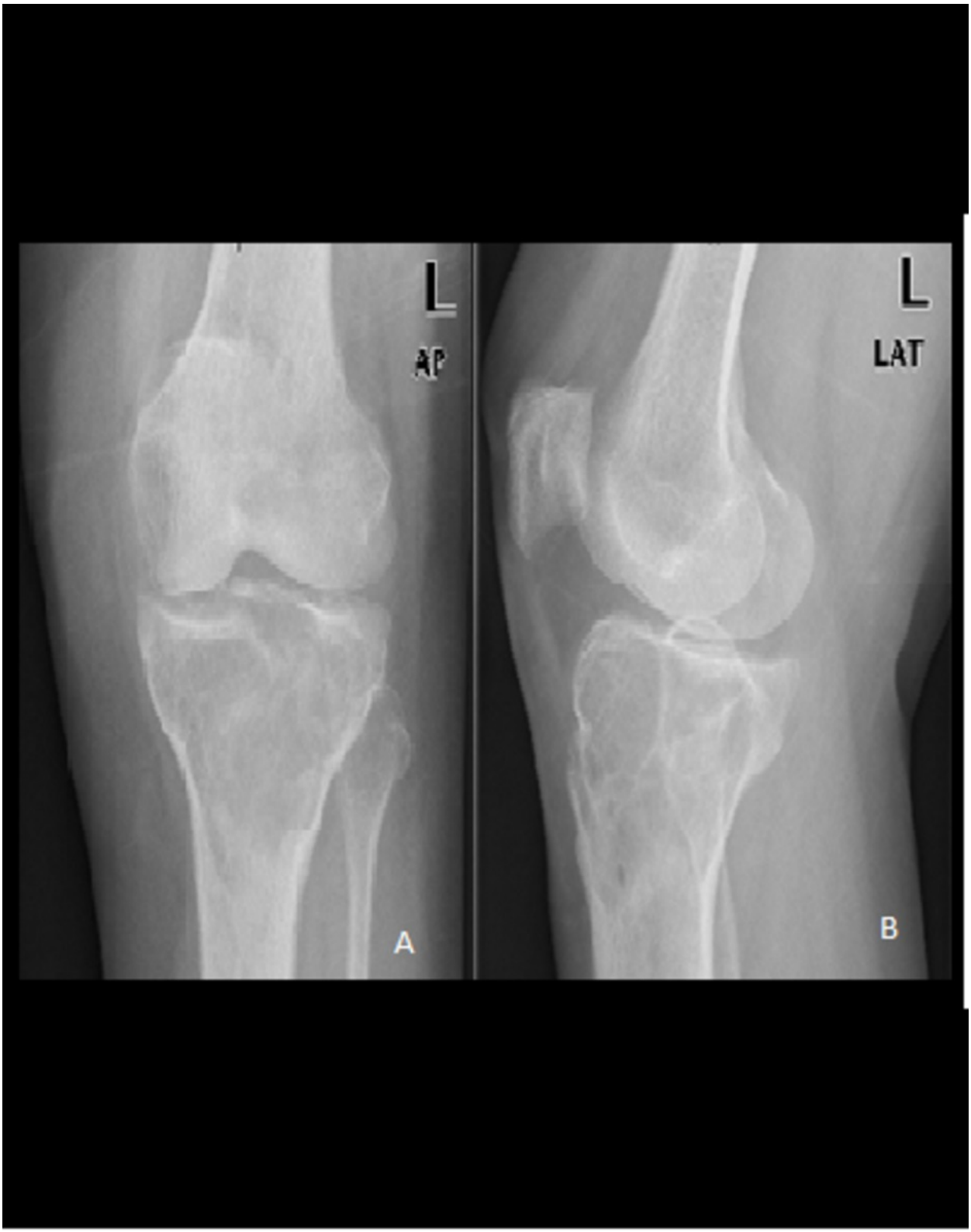

Fig. 8: Giant cell tumor. Frontal (A) and lateral radiographs of the left knee show a large geographic lytic lesion with a narrow zone of transition and no rim of sclerosis

(arrowheads), with central location on the metaepiphyseal side of the closed growth plate in the distal left tibia.

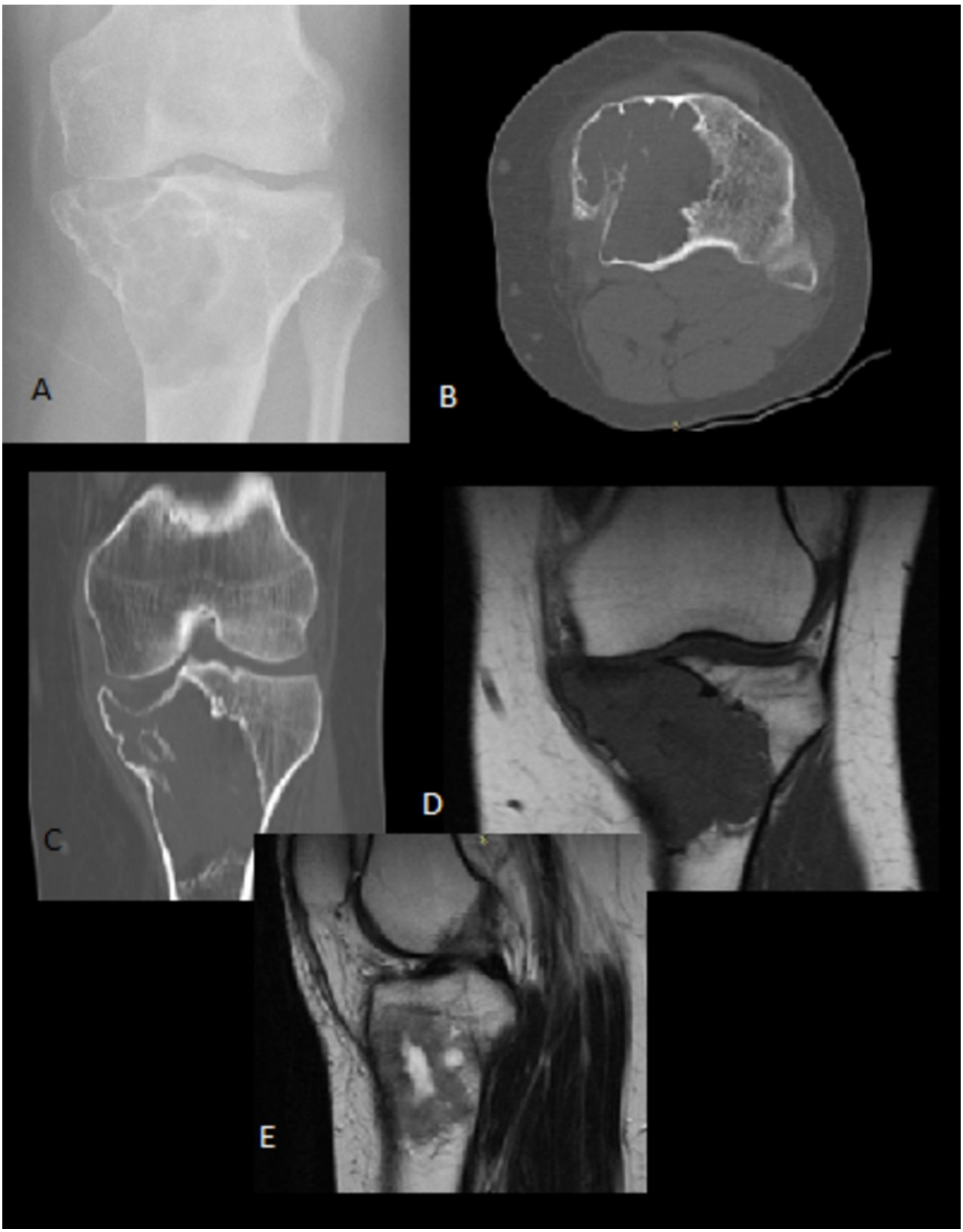

Fig. 9: Giant Cell Tumor. Anteroposterior radiograph (A) shows an eccentric lytic metaepiphyseal lesion in the distal tibia extending to subchondral bone. Axial computed tomography reformation (B) and coronal computed tomography reformation (C)show a mild expansion and sclerosis about the giant cell tumor. Coronal T1-weighted image (D), sagittal T2-weighted image (E) reveal a lesion with predominantly low intensity of signal on T1 weighted image and intermediate signal intensity with several high-signal-intensity foci corresponding to small cystic areas.

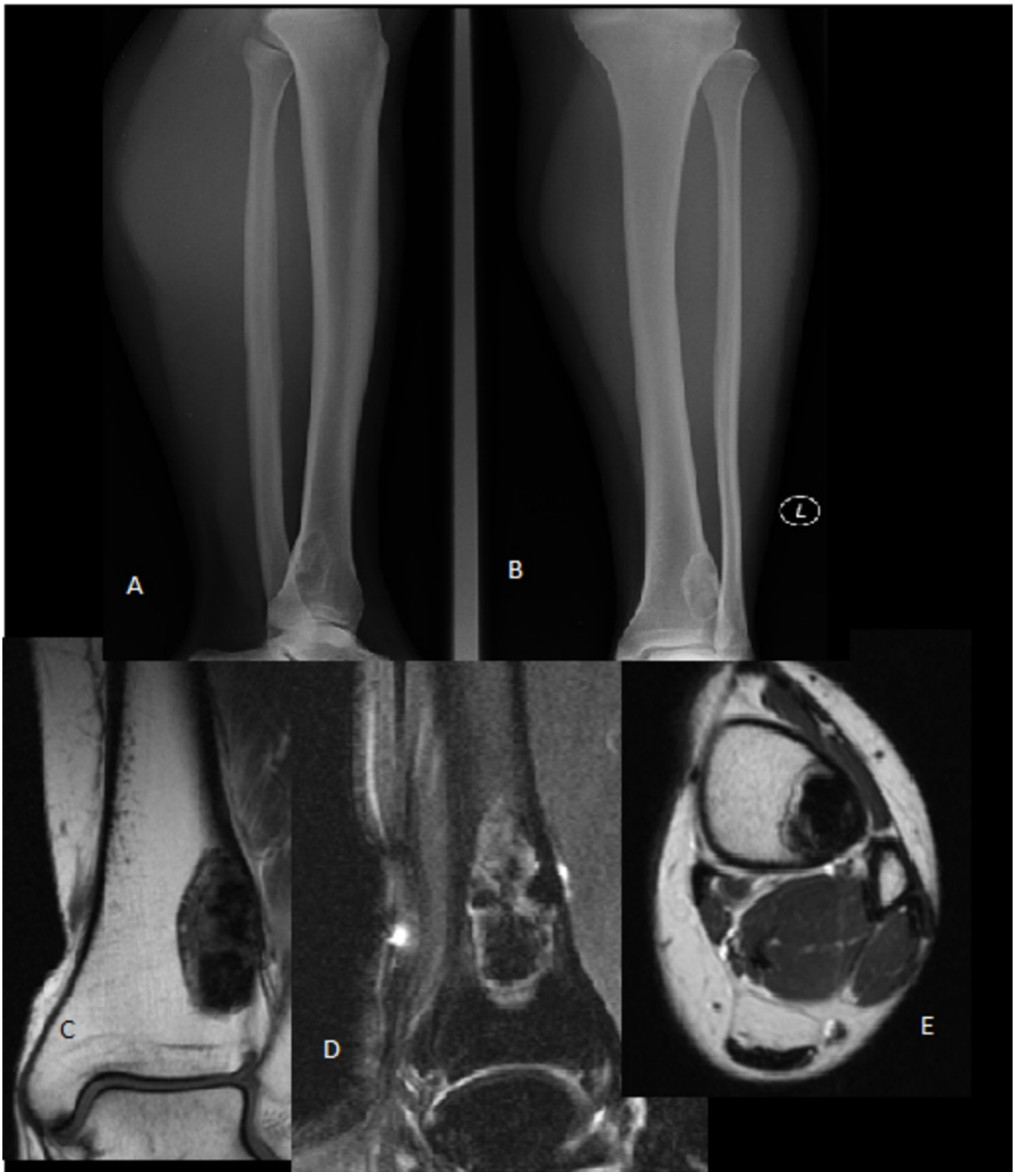

Fig. 10: Non-ossifying fibroma. Anterior-posterior (A) and lateral (B) radiographs of the left leg show a sharply demarcated asymmetrical, cortically based lytic lesion with a thin sclerotic rim, with slightly multiloculated appearance in the distal metadiaphyseal region of the left tibia. T1 coronal weighted image (C), T2 FS sagittal weighted image (D) and T2 axial weighted image (E)reveal a justacortical eccentric lesion, with well-defined borders and without cortical disruption. It is predominantly hypointense on all sequences, with some outlying areas of hyperintensity of signal on T2-weighted images.

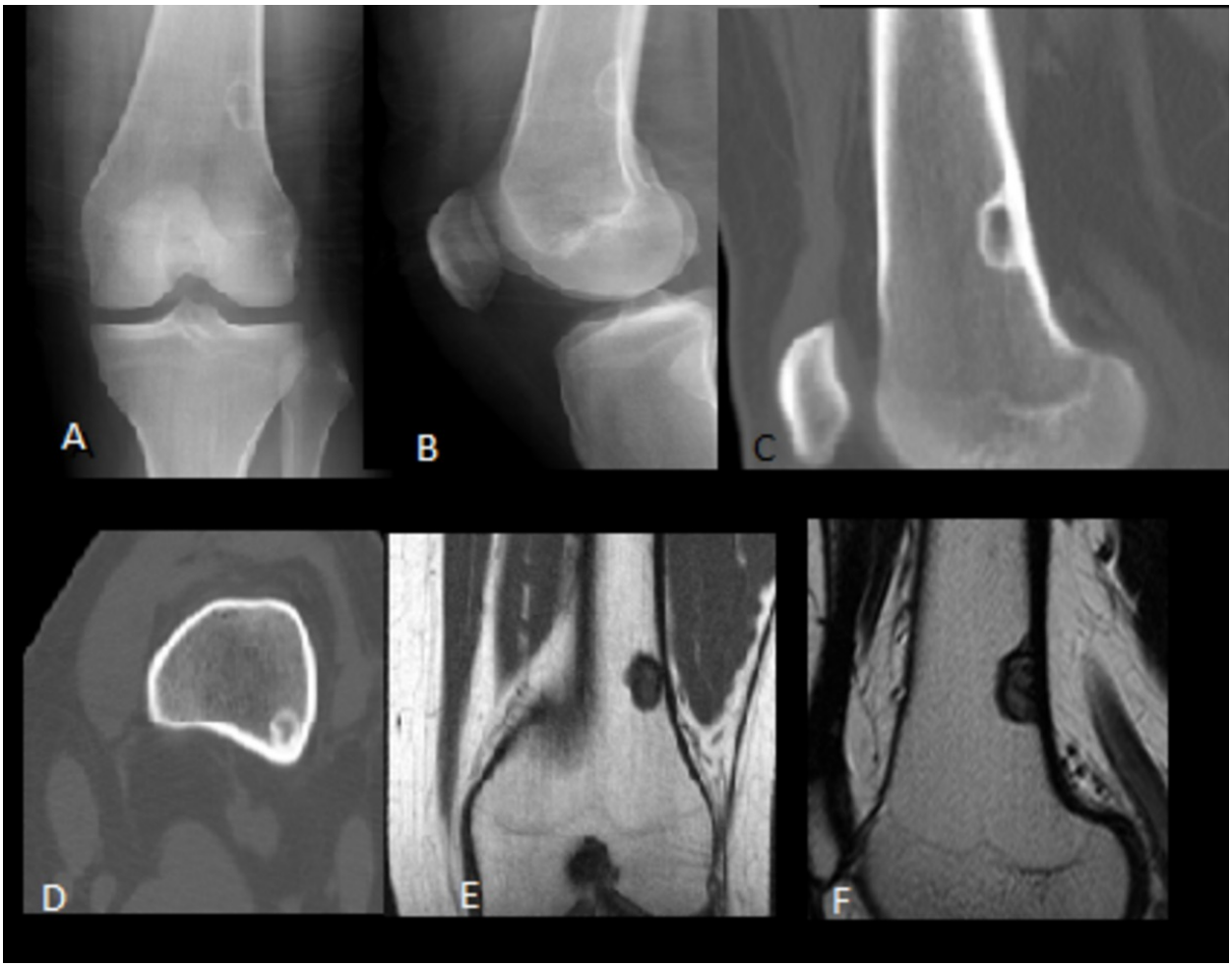

Fig. 11: Non-ossifying fibroma. Anterior-posterior and lateral radiographs of the left knee (A, B) show a small well-defined cortically based lytic lesions with a thin sclerotic rim in the distal meta-diaphyseal of the left femur. Sagittal and axial computed tomography reformations (C, D) of the same patient continue to show a typical non-ossifying fibroma. T1 coronal weighted image and T2 sagittal weighted image (E, F) reveals the same lesion. hypointensity of signal on T1-weighted images and hypointensity of signal on T2-weighted images. Note the hypointense halo on both sequences. There is no associated soft tissue mass or cortical disruption.

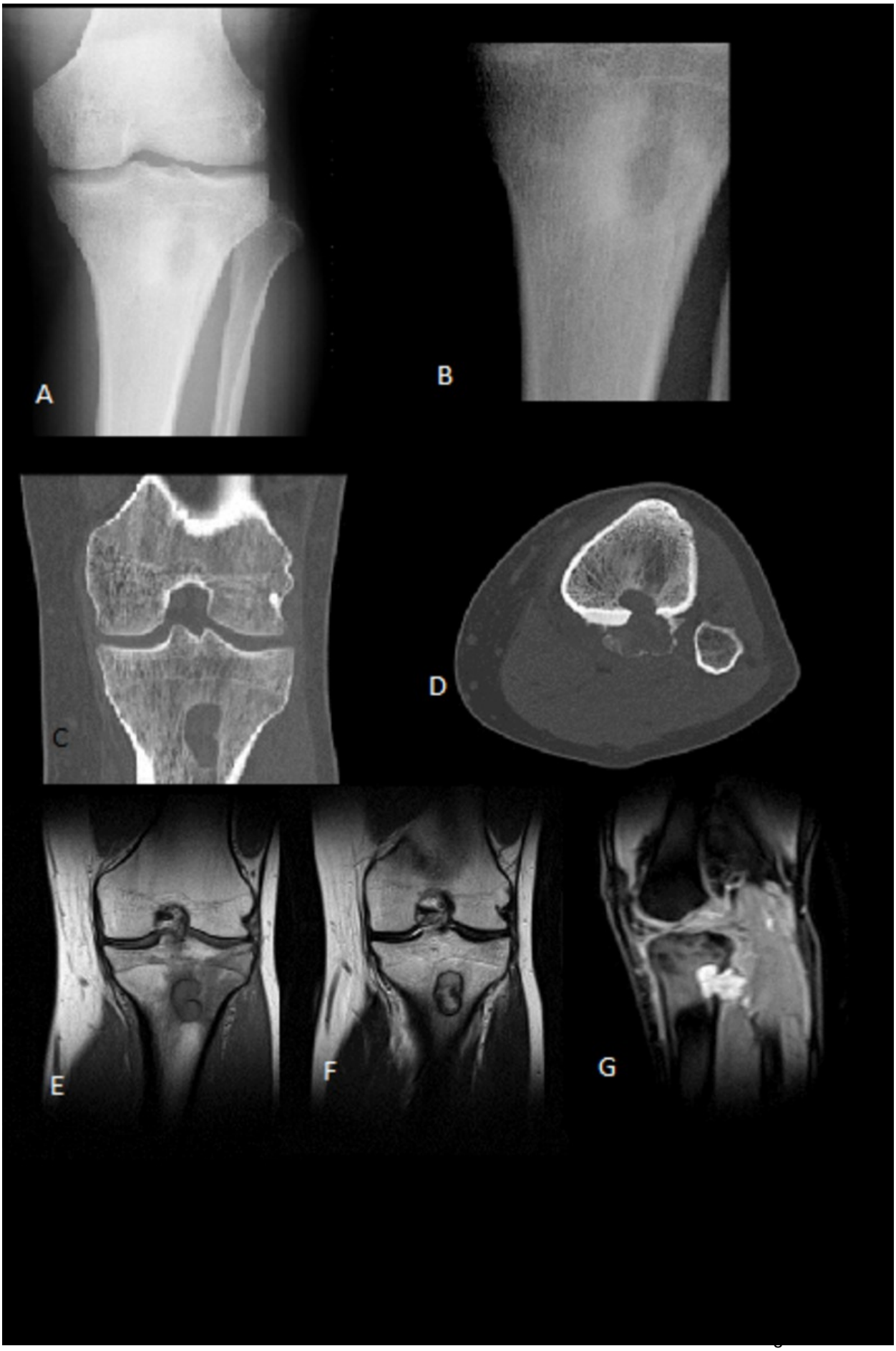
A
B
C
D
E
F
G

Fig. 12: Osteoblastoma. Frontal radiographs (A,B) show a lytic lesion with sclerotic pheripheral rim in the tibia. Coronal and axial computed tomography reformations (C, D) reveal a metaphyseal eccentric cortical lesion with calcified matrix. This lesion presents isointensity of signal on T1-weighted images (E) and slightly hyperintensity of signal on T2-weighted images (F), with surrounding bone marrow oedema. After gadolíneo administration (G) the lesion presents homogeneous enhancement.

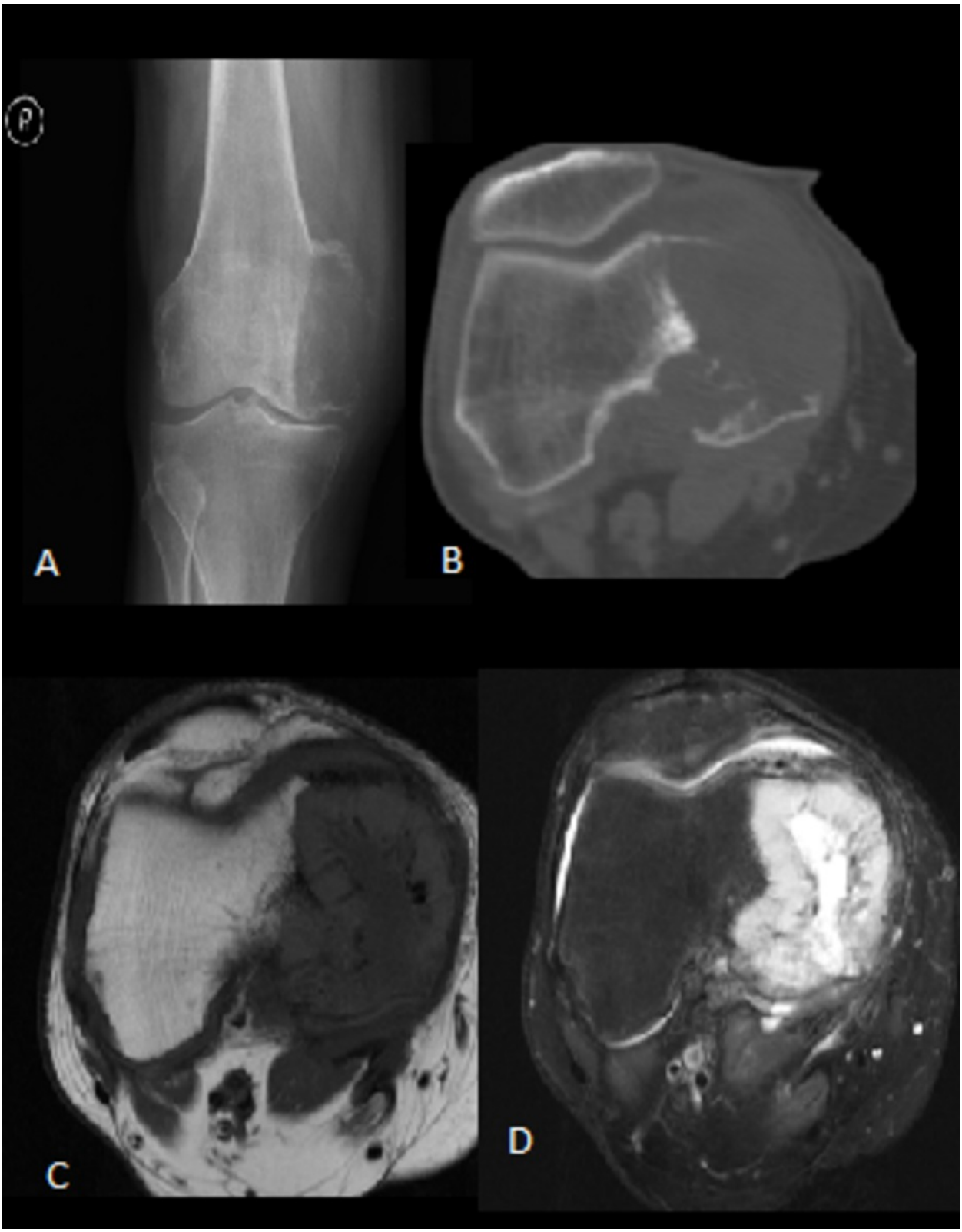

Fig. 13: Thyroid Carcinoma Bone Metastases. Frontal right Knee radiography (A) and axial computed tomography reformation (B) show a large lytic lesion, with eccentric location in the metaepiphyseal region of the medial femoral condyle. CT allows to better

appreciation of cortical disruption. Axial T1 (C) and axial T2- FS (D) weighted images show a heterogeneous lesion with central necrosis. There is small amount of joint effusion

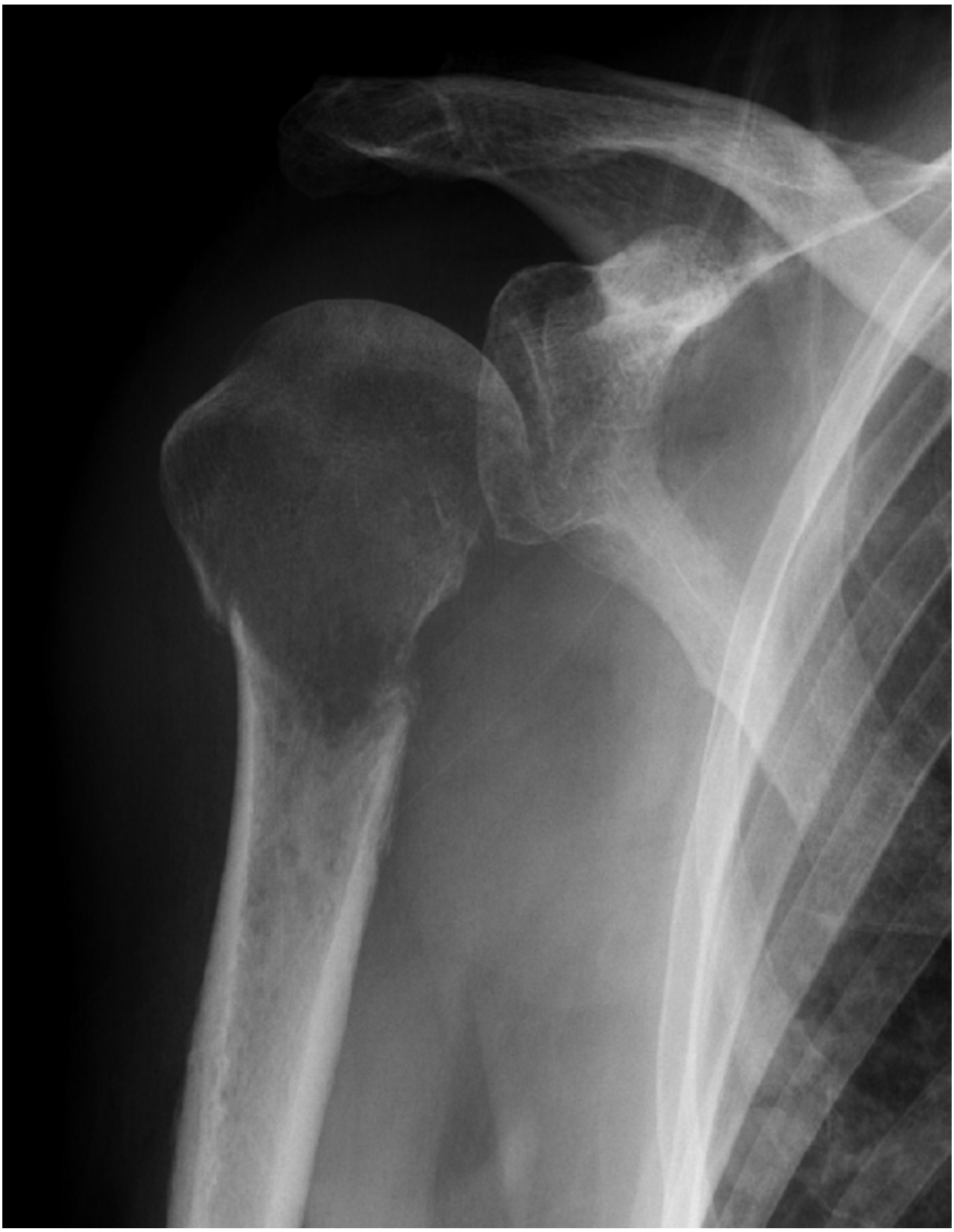

Fig. 14: Thyroid cancer bone metastases. Frontal radiography reveals a large lytic lesion with pathologic fracture located in the proximal humerus.

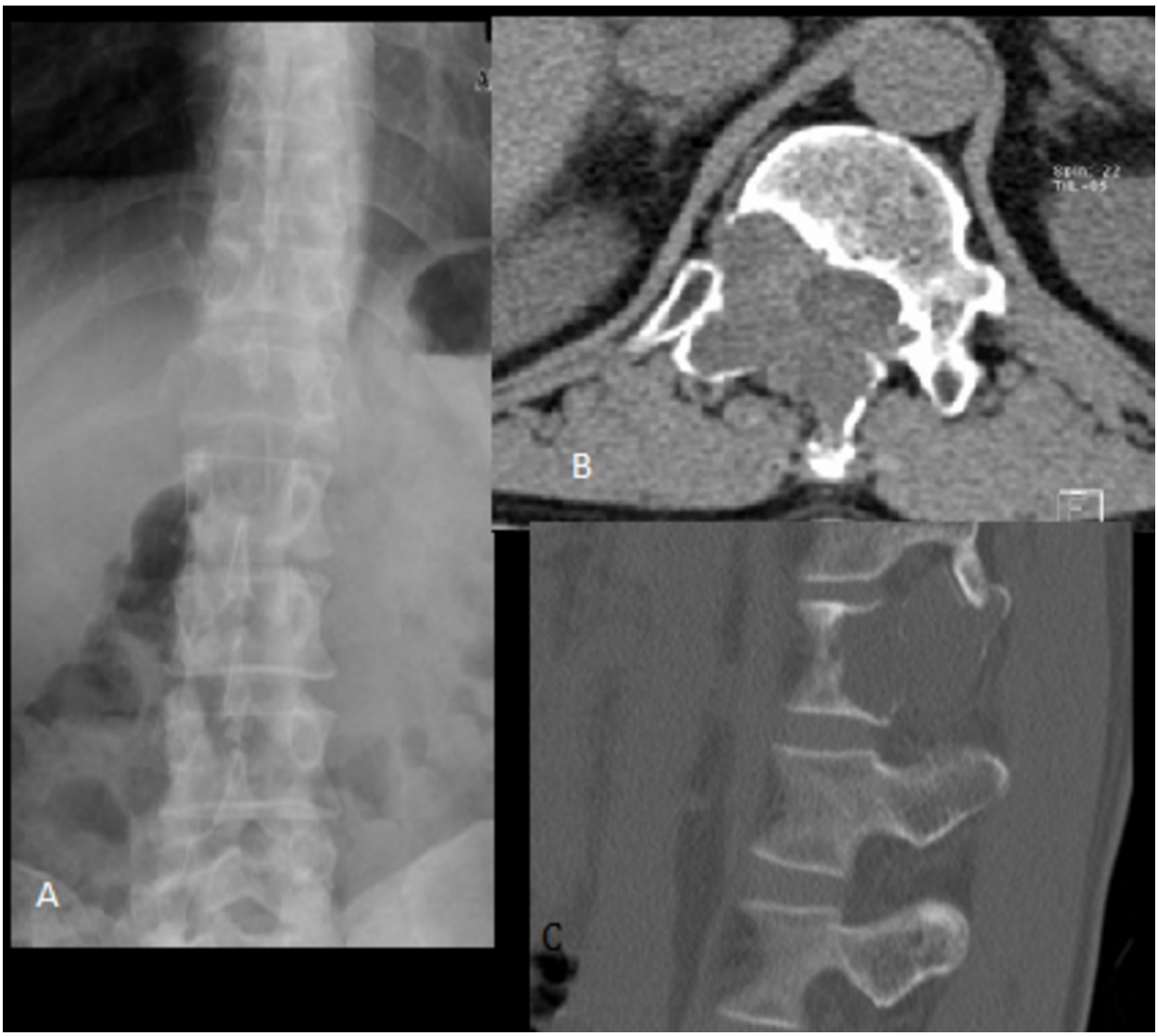

Fig. 15: Plasmacytoma. Frontal radiography (A) revealing a large well-defined lytic lesion in the first lumbar vertebra. Axial (B) and sagittal (C) computed tomography images allows better extension and cortical disruption assessment.

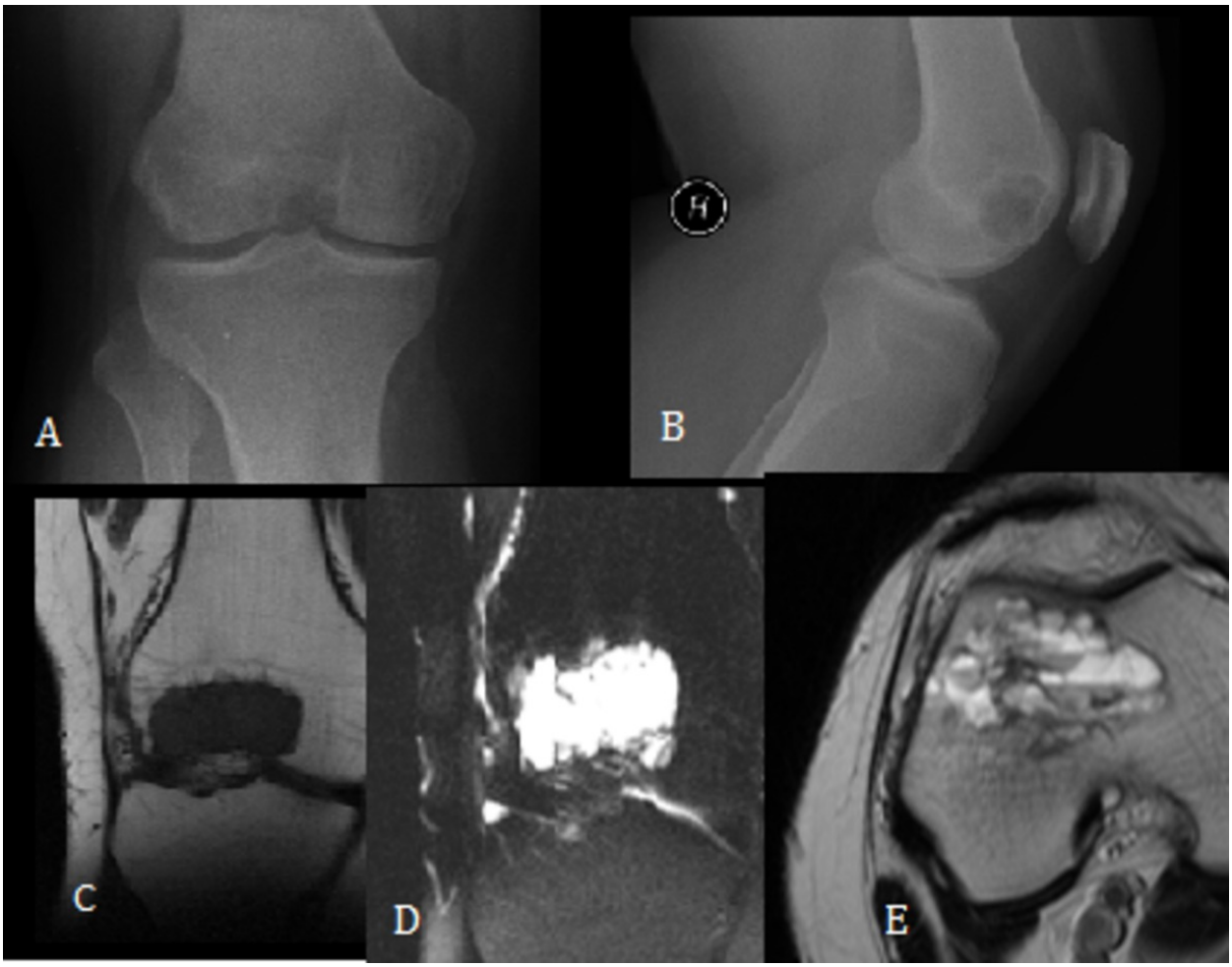

Fig. 16: Aneurysmal bone cyst. Frontal (A) and lateral (B) radiographs reveal a well-defined lytic lesion with sclerotic rim located in the central epiphysis with lateral extension. Coronal T1 weighted image (C), coronal fat suppression T2-weighted image (D) and axial T2 without fat supression weighted image (E) reveal a well-defined oval lesion in the epiphysis of the right femur. The lesion has a multiloculated appearance with fluid-fluid levels on T2-weighted images. It appears hypointense on T1 weighted images. No solid component, bone oedema or soft tissue mass associated

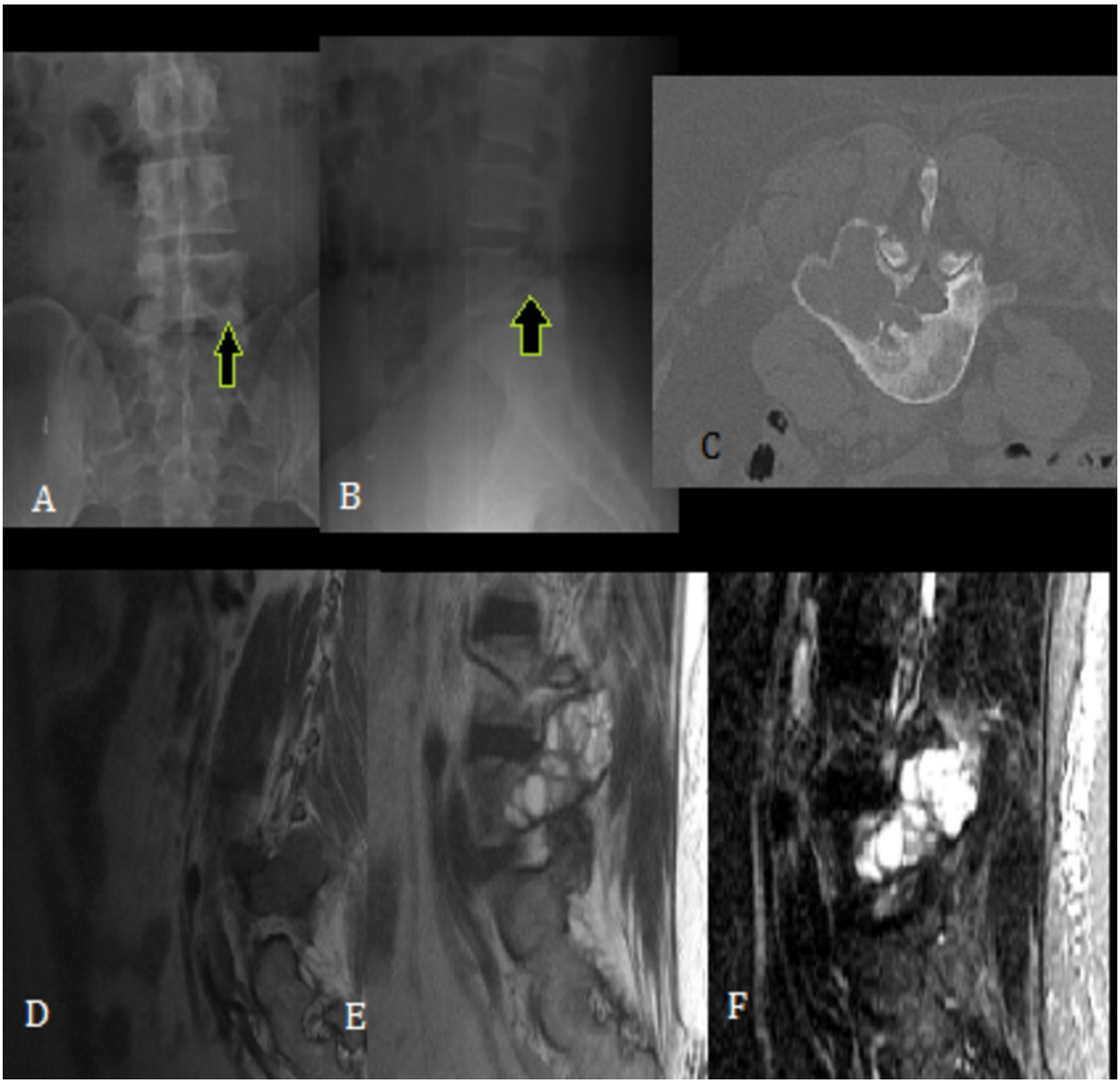

Fig. 17: Aneurysmal Bone cyst. Frontal and lateral radiographs (A, B) reveals a sharply demarcated lytic lesion in the left hemi body of the fifth lumbar vertebra (arrow). Axial computed tomography reformation image (C) shows a large expansible lytic lesion involving the left hemi body and posterior elements, without any evidence of periosteal reaction and with cortical disruption. Sagittal T1 and T2 weighted images (D,E), sagittal T2 turbo inversion recovery weighted image (F) show a lesion located in the pedicle, transverse apophasis and body of the fifth lumbar vertebra. The lesion expands beyond the bony limits and has a small endocanalar component without frank compression of the dural sac. This lesion presents a multiloculated appearance, with fluid-fluid levels and highly heterogeneous signal intensity on T2-weighted images and low intensity of signal on T1 weighted images.

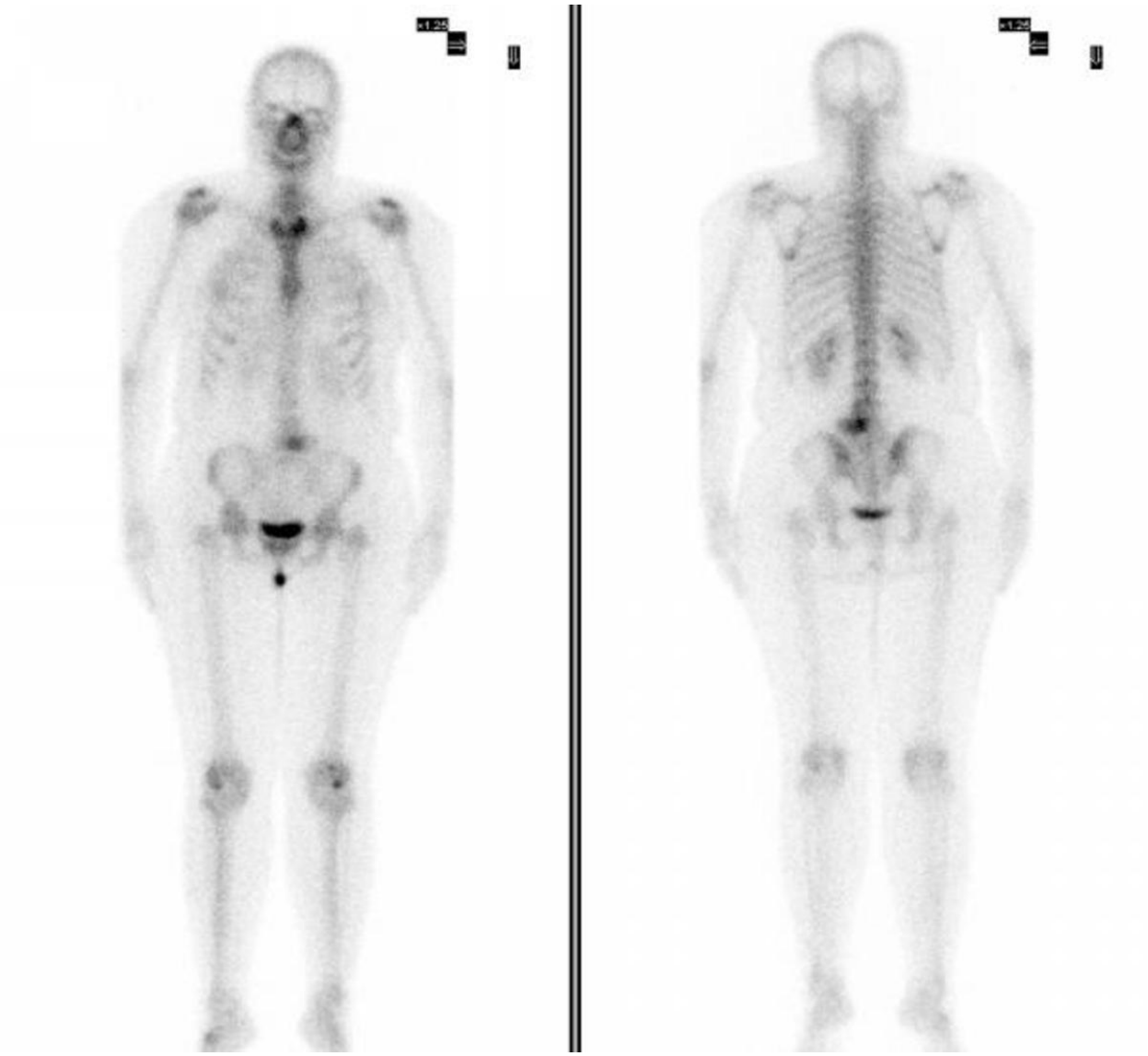

Fig. 18: Aneurysmal bone cyst. Bone scan (Same patient in figure 16) reveals increased osteoblastic activity with associated hyperaemia on the left side of the fifth lumbar vertebra.

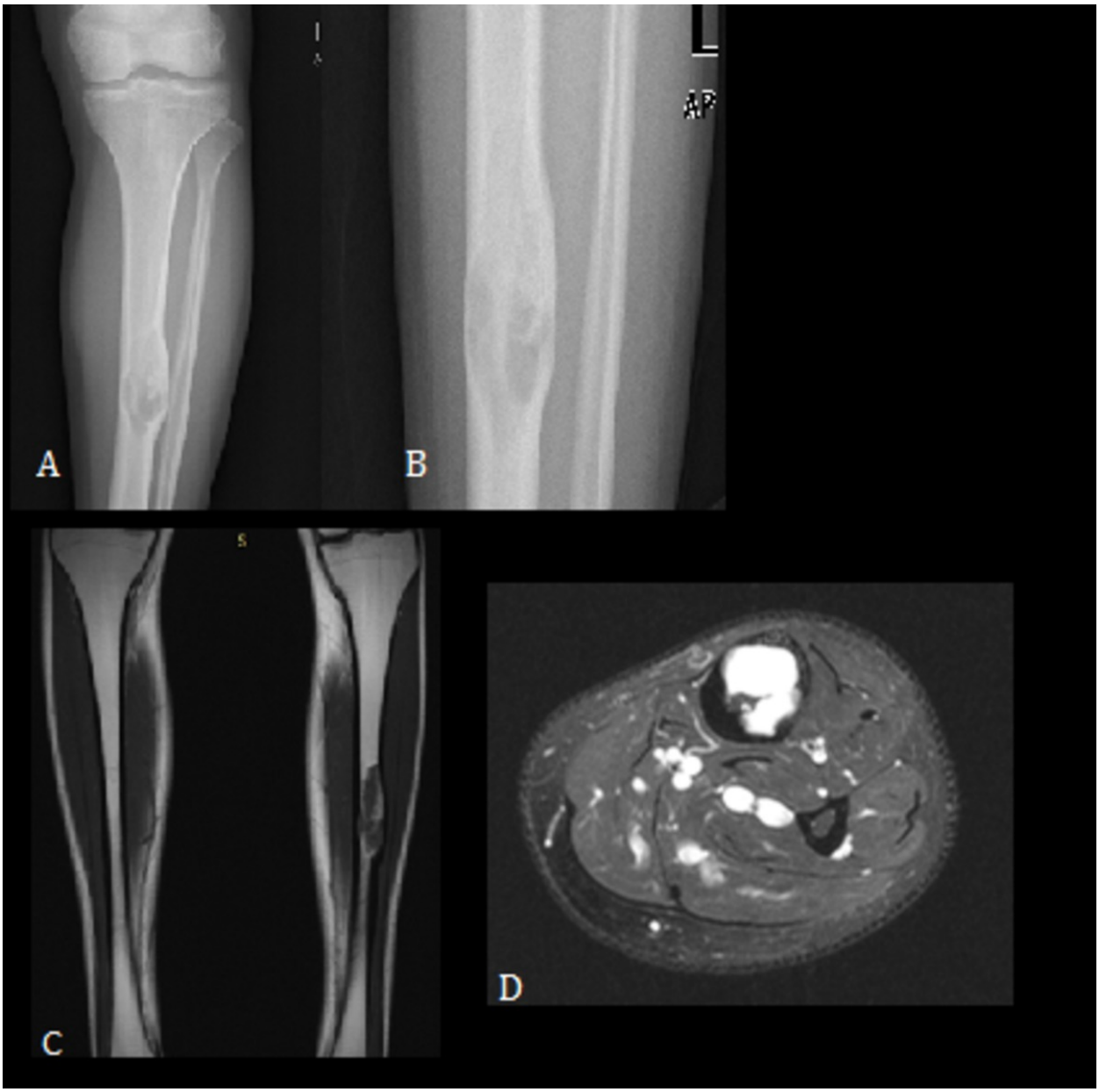

Fig. 19: Solitary bone cyst. Anterior-posterior (A) and lateral radiographs (B) reveal bone expansion with cortical thinning adjacent to a well-defined lytic lesion located in the middle third of the left tibia.Coronal T1 weighted image (C) axial T2 FS weighted image (B) show a intramedullary lesion located in the middle third of the left tibia with bone expansion and thinning of the adjacent cortical without disruption. This lesion has multiloculated areas with low signal intensity on T1 and high signal intensity on T2 weighted images.C

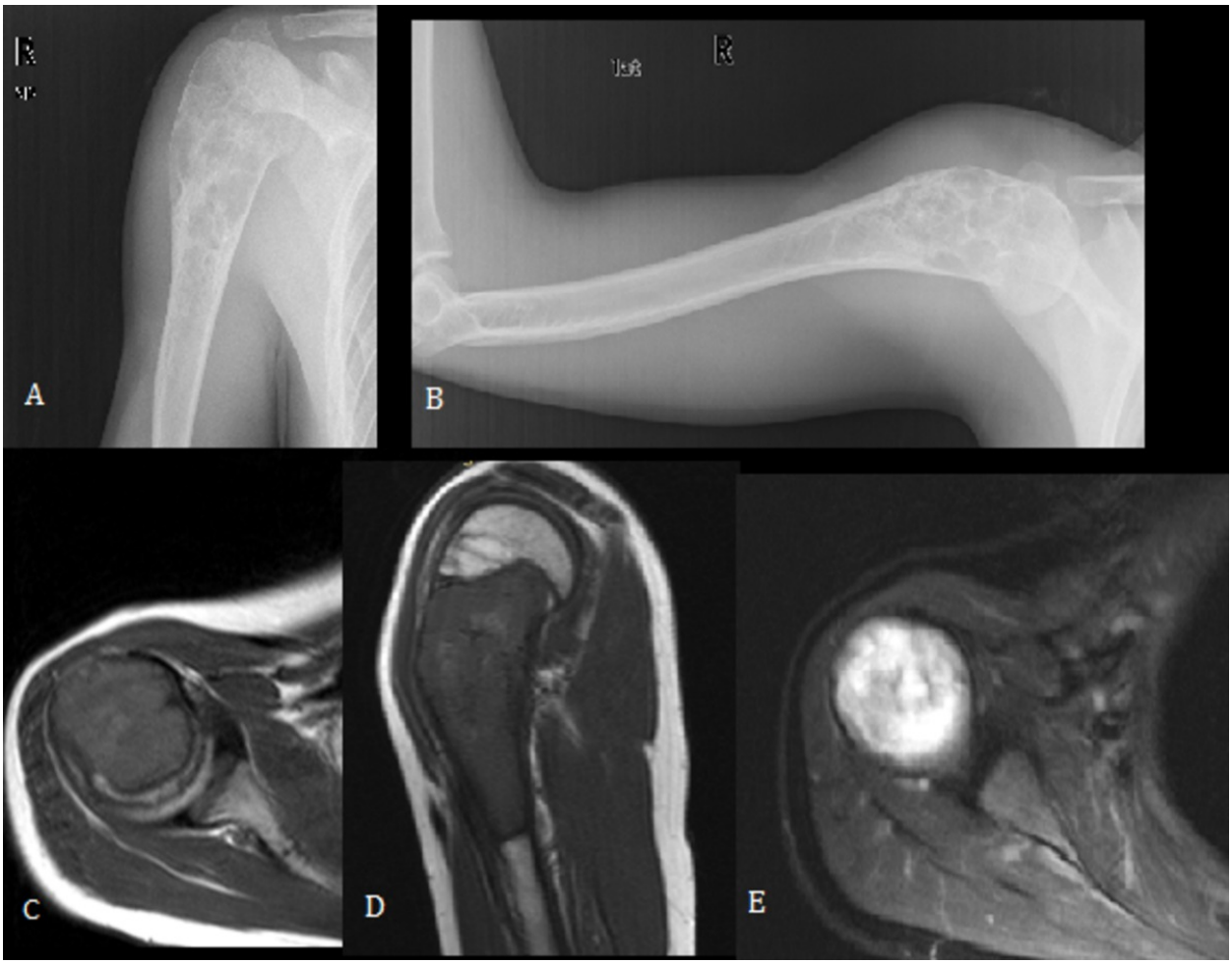

Fig. 20: Solitary bone cyst. Anterior-posterior (A) and lateral (B) radiographs of the left humerus shows an expansible medullary, radiolucent lesion in the proximal humeral metaphysis extending to the growth plate is seen. T1 axial and sagittal (C, D) weighted image and T2 fs weighted image (E) reveal a hypointense on T1 weighted image with areas of hyperintensity on T2 weighted images lesion.

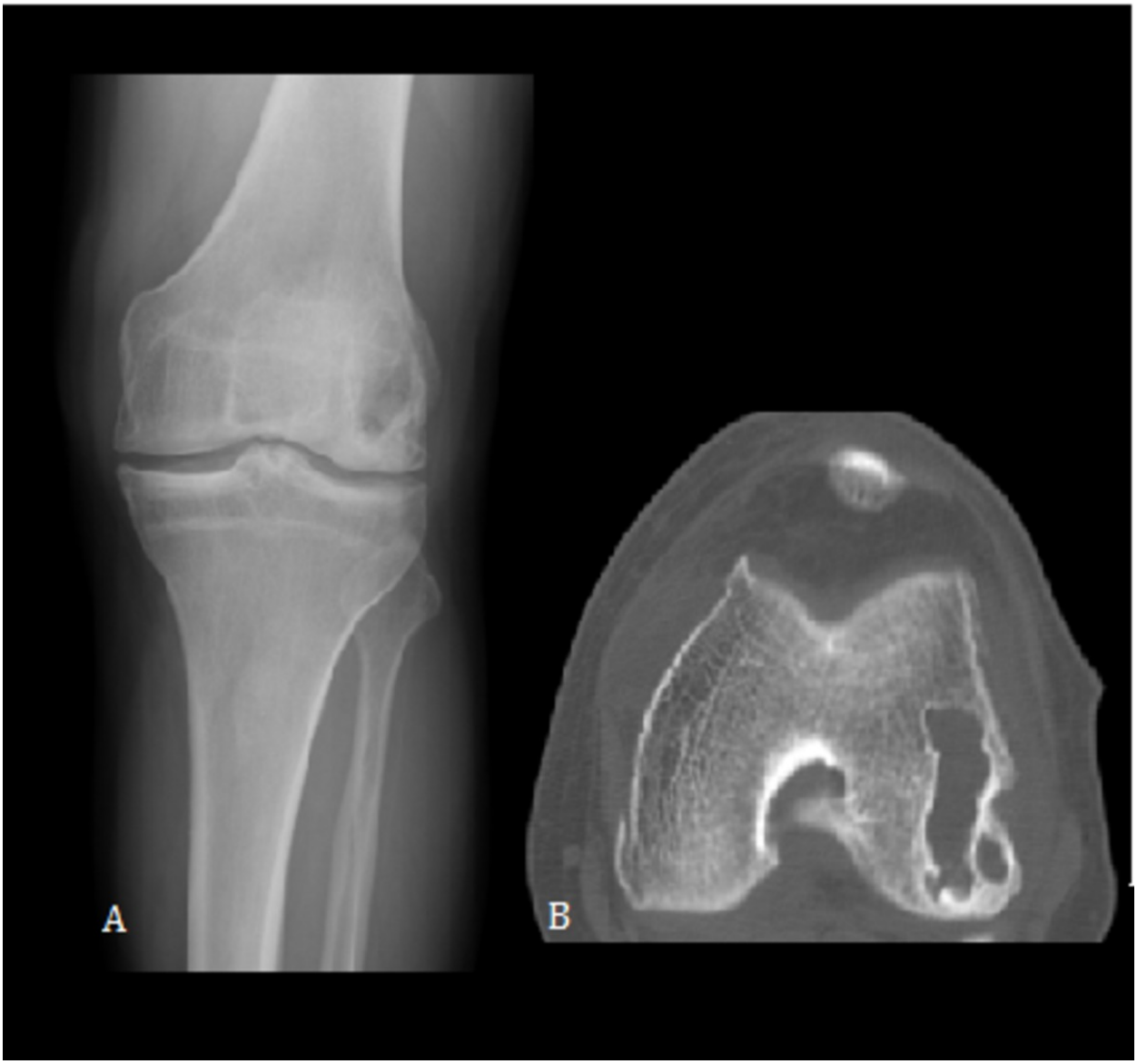

Fig. 21: Solitary bone cyst. Anterior-posterior radiography (A) of the left knee reveals a small sharply marginated lesion located in the lateral condyle. Axial computed tomography reformation (B) show a well-defined lesion, with sclerotic rim and multilocated appearance caused by prominent ridges of bone.

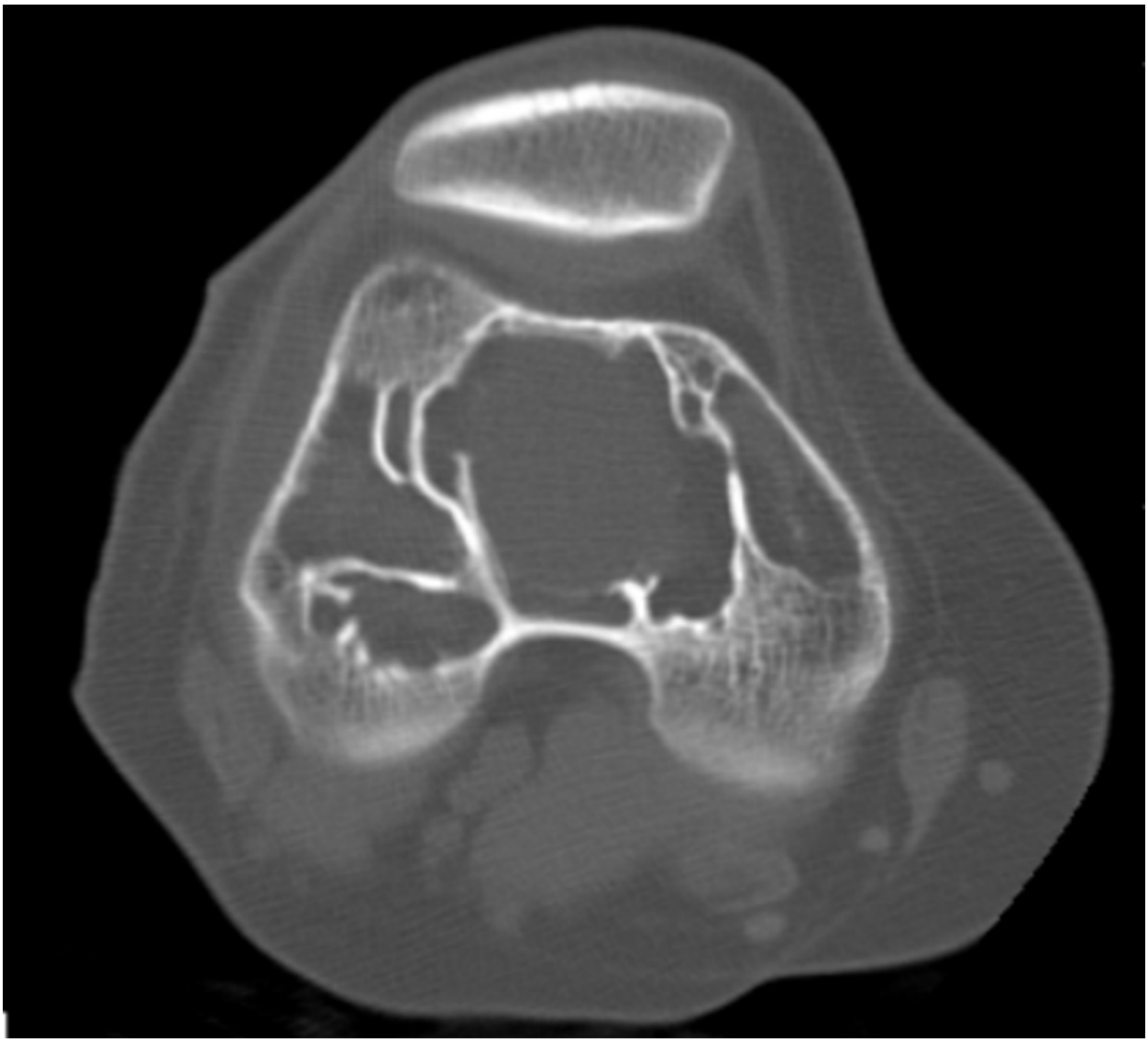

Fig. 22: Solitary bone cyst. Axial computed tomography reformation of the right femoral bone reveals a multiloculated appearance well-defined lytic lesion.

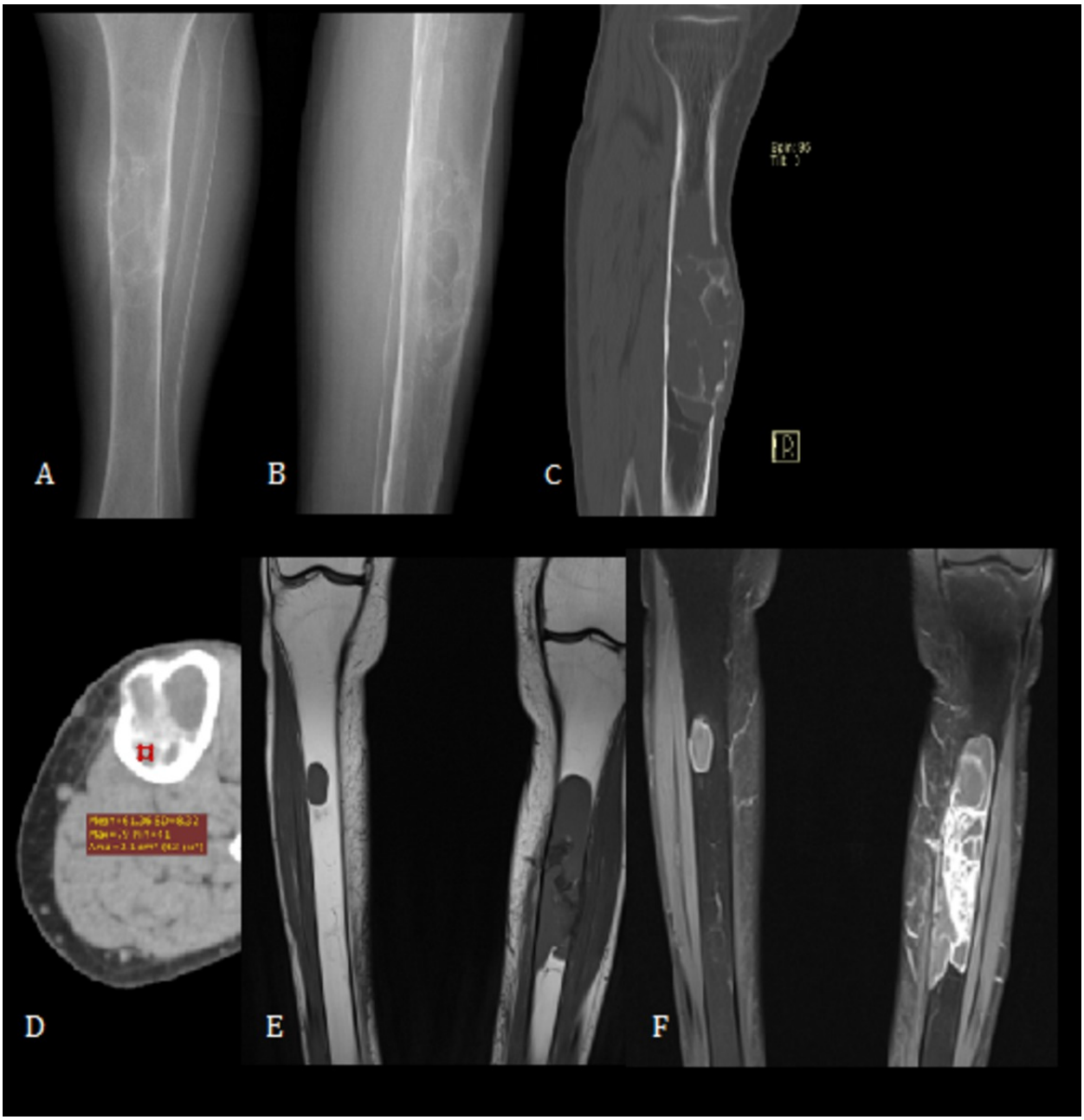

Fig. 23: Hyperparathyroidism - Brown Tumors.Anteroposterior radiography (A) and Lateral radiography (B) show an eccentric expansive lytic well-marginated lesion with multiple septae in the left tibial diaphysis. Sagittal (C)and axial (D)computed tomography reformations show an expansive lesion with multiple septae with attenuation values of blood. Coronal T1 weighted image (D) and Coronal T1 FS after gadolinium administration (E) reveal a large eccentric hypointense well-defined lesion affecting the left tibial diaphysis and a smaller cortical lesion located in the right tibial diaphysis. Absence of soft tissue expansion.

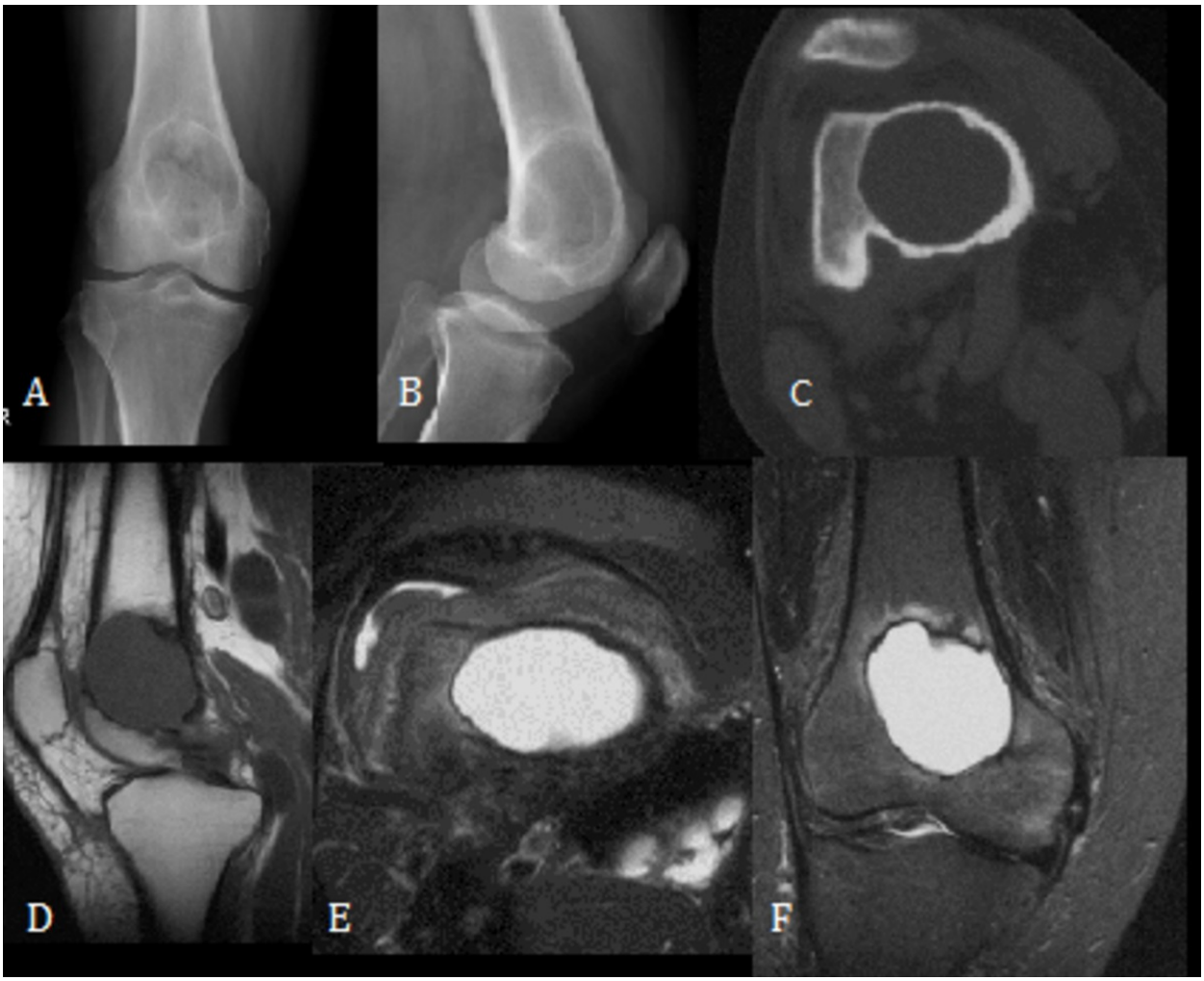

Fig. 24: Brodie's abscess. Frontal (B) and lateral (A) radiographs and axial computed tomography reformation (C) show a lytic lesion, with sclerotic margins located in medial malleolus of the right femur. Sagittal T1-eighted image (D), axial T2 and coronal T2 weighted images show a low intensity of signal, with surrounding lower bone marrow signal on T1-weighted images. T2 weighted images show a hyperintense lesion with surrounding bone marrow oedema.

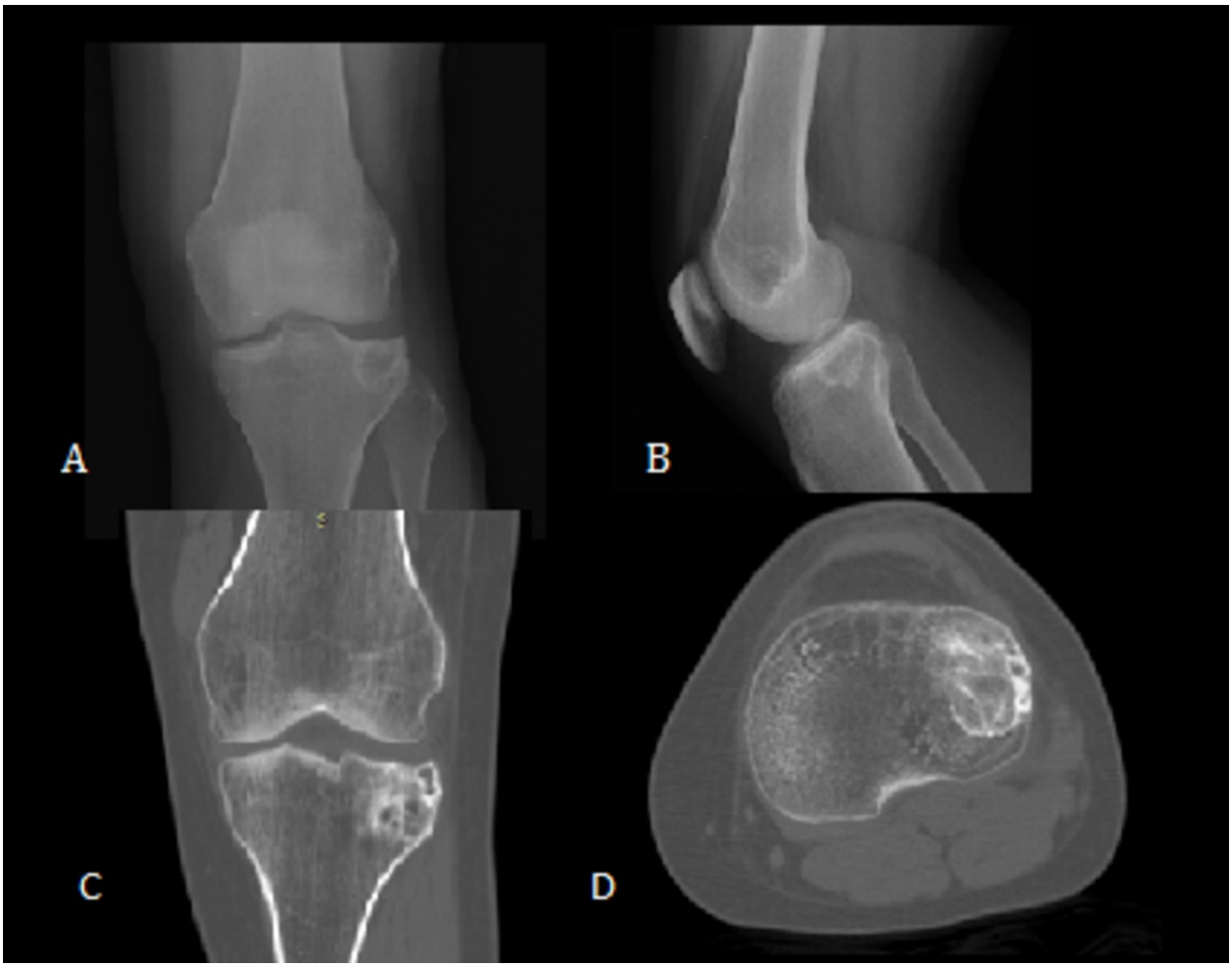

Fig. 25: Chondroblastoma. Anterior-posterior (A) e lateral (B) radiographs, Coronal (C) and axial (D) computed tomography reformations of the left knee reveal a well-demarcated lytic lesion in the proximal epiphysis of the left tibia,with chondroid matrix, surrounded by a thin sclerotic rim.

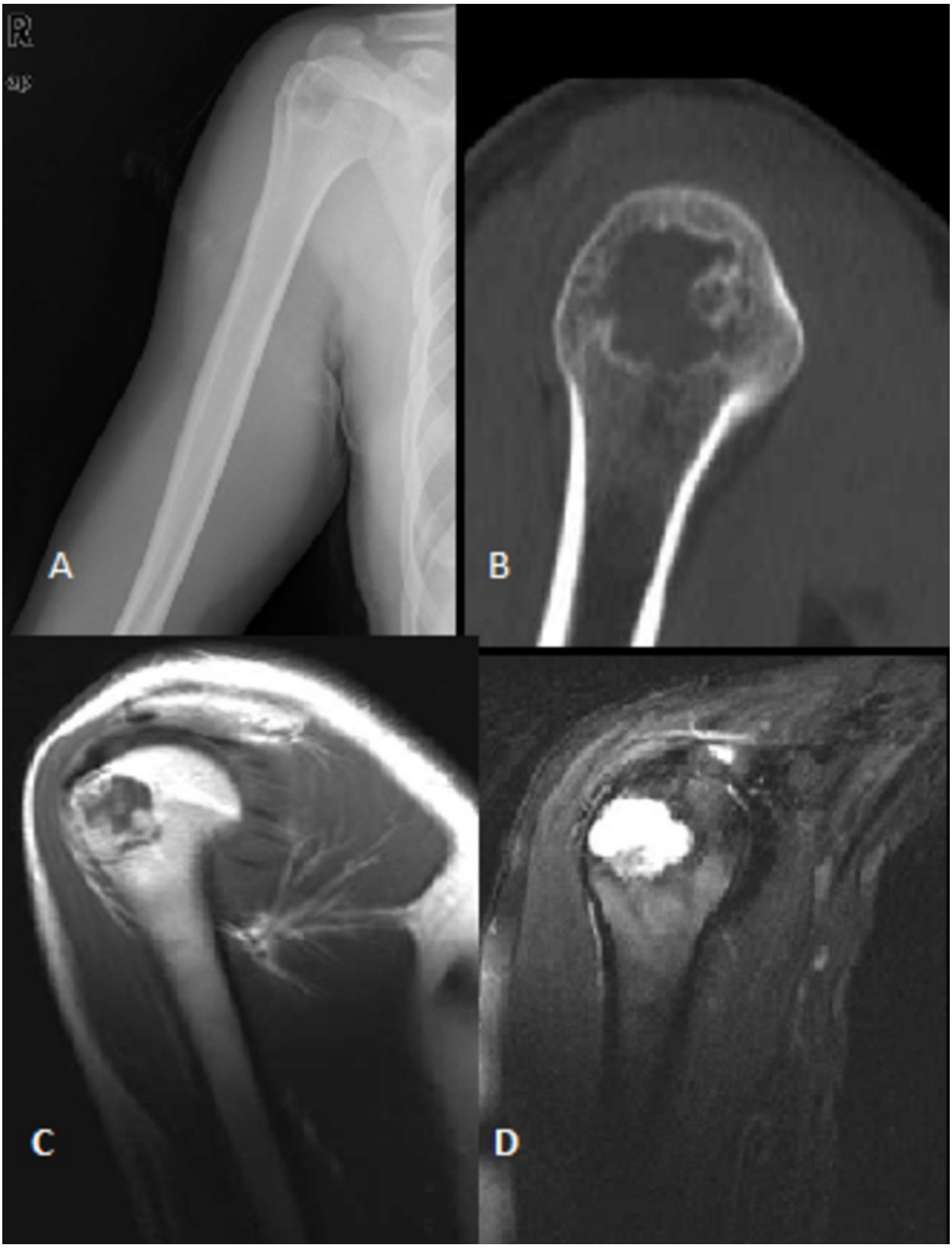

Fig. 26: Chondroblastoma: Anteroposterior (A) radiograph and sagittal (B) computed tomography reformation of the right arm show a well-demarcated lytic lesion in the

proximal epiphyseal humerus, surroundedby a thin sclerotic rim. Sagital T1- (C) and coronal fat-suppressed T2-weighted (D) images show a lobulated lesion in the proximal epiphyseal humerus. The lesion is isointense to muscle on T1-weighted image and shows heterogeneous high signal intensity on T2-weighted image. There is also bone marrow oedema.

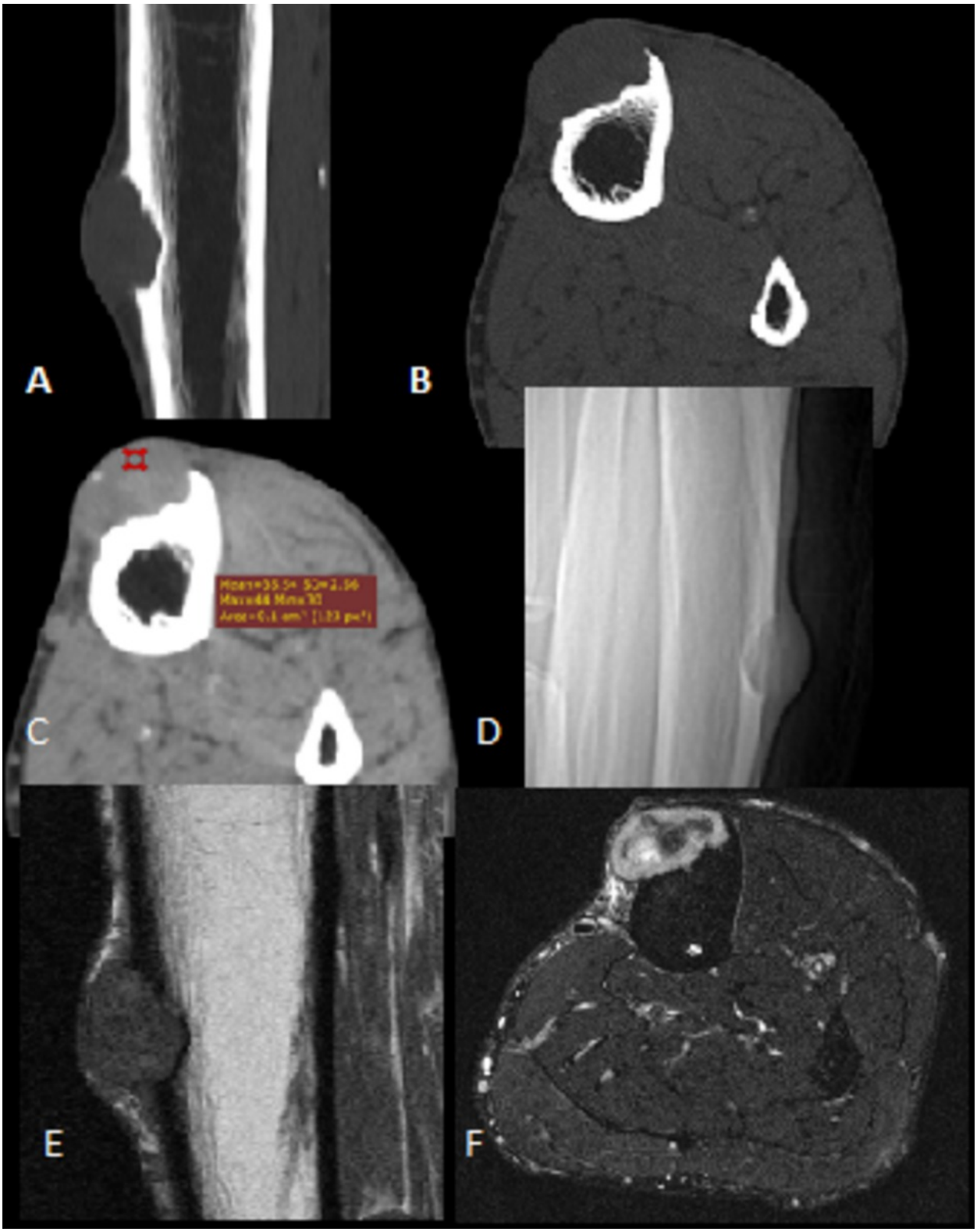

Fig. 27: Chondromyxoid fibroma. MPR thick (A) and axial computed tomography reformations (B, C) show an eccentric well-defined lytic lesion, with chondroid matrix, and a punctate calcification in the left tibia. The computed tomography orientation scout (D) reveals an oval, well-defined, sharply marginated eccentric lytic lesion in the left

tibia.Sagittal T1 weighted image (E) and axial T2 weighted image (F) reveals a low signal intensity eccentric lesion on T1-weighted images and with heterogeneous high signal intensity on T2-weighted images located.

Table 1: Differential Criteria for Benign Osteolytic Bone Lesions Mnemonic: FEGNOMASHIC			
Fibrous dysplasia: No pain or periosteal reaction; if in tibia, mention adamantinoma			
Enchondroma: Presents with calcification, except in phalanges; no pain or periostitis			
Eosinophilic granuloma: Must be younger than 30 years			
Giant Cell Tumor: Epiphysis must be closed; should be epiphyseal/metaphyseal and abut the articular surface; eccentric; well-defined but non-sclerotic border			
Non-ossifying fibroma: Younger than 30 years; no pain or periostitis			
Osteoblastoma: Mention when aneurysmal bone cyst is considered, even if the patient is older than 30 years			
Metastatic disease and Myeloma: Older than 40 years.			
Aneurysmal bone cyst: Younger than 30 years; expansible			
Solitary bone cyst: Central location; younger than 30 years; no pain or periostitis			
Hyperparathyroidism (Brown tumor); Evidence of hyperparathyroidism			
Infection: If adjacent to a joint, must involve the joint (weak)			
Chondroblastoma: Younger than 30 years; epiphyseal			
Chondromyxoid fibroma: Mention when considering non-ossifying fibroma			
Younger than 30 years	**No Periostitis or Pain**	**Epiphyseal**	**Multiple lesions**
Eosinophilic granuloma	Fibrous dysplasia	Chondroblastoma	Fibrous dysplasia
Aneurysmal bone cyst	Enchondroma	Infection	Eosinophilic granuloma
Non-ossifying fibroma	Non-ossifying fibroma	Giant cell tumor	Enchondroma
Chondroblastoma	Solitary bone cyst	Geode	Metastasis and myeloma
		(Eosinophilic and Aneurysmal bone cyst are optional)	Hyperparathyroidism
			Infection

Table 1: Table 1: Differential Criteria for Benign Osteolytic Bone Lesions Mnemonic: FEGNOMASHIC (Adapted from Helms C. Fundamentals of Skeletal Radiology. 3th edition, Elservier 2004.)

Conclusion

Radiologists should be familiar with the main imaging findings of well-defined osteolytic tumours and the signs suggesting a benign or malignant aetiology of these lesions, enhancing the diagnostic performance and improving management of these patients.

Personal information

Y. Costa[1], L. Andrade[2], M. Magalhaes[2], M. Diniz[1], J. F. Pisco[1], L. Curvo Semedo[2], C. B. Marques[2], F. Caseiro Alves[2]; [1]Faro/PT, [2]Coimbra/PT

1. Serviço de Radiologia Centro Hospitalar do Algarve, Faro, Portugal

2. Serviço de Imagem Médica, Centro Hospitalar e Universitário de Coimbra, Faculdade de Medicina de Coimbra. Medical Imaging Department and Faculty of Medicine, University Hospital of Coimbra, Portugal

References

1. B.J. Manaster; David A. May; David G. Disler. Musculoskeletal Imaging: The Requisites in Radiology Third Edition; Mosby Elsevier 2007

2. A. M. Davies; M. Sundaram; S. L. J. James. Bone Tumors and Tumor-Like Lesions; Springer-Verlag Berlin Heidelberg 2009

3. Sumit Mehta; Janio Szklaruk; Silvana C. Faria; A. Kevin Raymond; Gary J. Whitman. Chondromyxoid Fibroma of the Sacrum and Left Iliac Bone; AJR 2006; 186:467-469

4. Henry j. Mankin; Francis J. Hornicek; et al. Aneurysmal Bone Cyst: A review of 150 patients; JCO 2005; 23; 6756-6762

5. R. Suneja, R. J. Grimer, M. Belthur, L. Jeys, S. R. Carter, R. M. Tillman, and A. M. Davies. Chondroblastoma of bone: long-term results and functional outcome after intralesional curettage. J Bone Joint Surg Br July 2005 87-B:974-978

6. M D Murphey; D J Flemming; S R Boyea; J A Bojescul; D E Sweet, and H T Temple. Enchondroma versus chondrosarcoma in the appendicular skeleton: differentiating features.. RadioGraphics 1998 18:5, 1213-1237

7. Kimberly A. Fitzpatrick; Mihra S. Taljanovic; Donald P. Speer; Anna R. Graham; Jon A. Jacobson; George R. Barnes, and Tim B. Hunter. Imaging Findings of Fibrous Dysplasia with Histopathologic and Intraoperative Correlation. AJR2004 182:6, 1389-1398

8. Corey J. Chakarun; Deborah M. Forrester; Christopher J. Gottsegen; Dakshesh B. Patel; Eric A. White;George R. Matcuk, Jr.Giant Cell Tumor of Bone: Review, Mimics, and New Developments in Treatment. DOI: http://dx.doi.org/10.1148/rg.331125089

9. Chew FS, Huang-hellinger F. Brown tumor. AJR Am J Roentgenol. 1993;160 (4): 752.

10. Knowles, N. G., Smith, D. L. and Outwater, E. K. (2008), MRI diagnosis of brown tumor based on magnetic susceptibility. J. Magn. Reson. Imaging, 28: 759-761. doi: 10.1002/jmri.21441

11. Kroon HM, Schurmans J. Osteoblastoma: clinical and radiologic findings in 98 new cases. Radiology. 1990 Jun;175(3):783-90.

12. http://www.ajol.info/index.php/sajr/article/viewFile/34502/6426

13. http://www.radiologyassistant.nl/en/p4bc6176e56228/bone-tumor-well-defined-osteolytic-tumors-and-tumor-like-lesions.html

14. http://radiopaedia.org/

15. C-1661 Bone tumors of cartilaginous origin: a pictorial review- DOI 10.1594/er2013/C-1661

16. C-1975 Benign bone tumors: diagnosis and therapeutic options - DOI: 10.1594/ecr2012/C-1975

16. Helms C. Fundamentals of Skeletal Radiology. 3th edition, Elservier 2004.